

PANCREATOTOXICITY OF ETHANOL EXTRACT OF *DIALIUM GUINEENSE* STEM BARK IN RATS

Abu^{1*} O.D., Alegun² O. and Ojo³ A.U.

¹Department of Biochemistry, Faculty of Life Sciences, University of Benin, Benin City, Nigeria.

²Department of Chemistry, College of Arts and Sciences, University of Kentucky, Lexington, USA.

³Department of Chemical Engineering, College of Engineering and Computing, University of South Carolina, USA.

*Corresponding Author: Abu O.D.

Department of Biochemistry, Faculty of Life Sciences, University of Benin, Benin City, Nigeria.

Article Received on 16/09/2022

Article Revised on 05/10/2022

Article Accepted on 26/10/2022

ABSTRACT

Aim: To investigate the pancreatotoxicity of ethanol extract of *Dialium guineense* stem bark in Wistar rats.

Materials and Methods: Wistar rats (n = 35) weighing 160 to 180 g were randomly assigned to seven groups (5 rats per group). One group served as control, while rats in the treatment groups received varied doses of the extract (200 - 5000 mg/kg body weight, bwt) for 28 days. Indices of pancreatic function were measured. **Results:** Percentage increases in body weights of rats treated with ethanol extract of *D. guineense* stem bark were significantly reduced, relative to the control group ($p < 0.05$), but there were no significant differences in the relative pancreas weights among the groups ($p > 0.05$). Treatment with the extract did not elicit any significant differences in the activities of α -amylase as well as pancreatic malondialdehyde (MDA) level among the groups ($p > 0.05$). Similarly, the extract did not significantly alter the normal architecture of rat pancreas. **Conclusion:** The results obtained in this study have shown for the first time that the plant extract is not toxic to rat pancreas.

KEYWORDS: α -Amylase, *Dialium guineense*, Histology, Malondialdehyde, Pancreatic function.

INTRODUCTION

Acute pancreatitis (AP) may be caused by exposure to certain drugs/compounds.^[1] Literature has shown that about 20 % of the top most prescribed drugs are toxic to the pancreas.^[2,3] Some causes of pancreatitis are gallstones, alcohol abuse, hypercalcemia, hypertriglyceridemia, viral infection, trauma as well as cardiovascular and anti-inflammatory analgesic agents.^[4] Pancreatotoxicity due to direct exposure to drugs results in subclinical pancreatic damage.^[5] Two out of the following three features are required for a diagnosis of AP: (1) abdominal pain characteristic of acute pancreatitis; (2) serum amylase and/or lipase levels ≥ 3 times the upper limit of normal; and (3) characteristic findings of AP on CT scans.^[6]

As a localized inflammation of the pancreas the disease is commonly mediated by the premature activation of digestive enzymes retained in the pancreas. Although this condition may resolve by itself within days, its persistence could cause pancreatic dysfunction and failure of other remote organs/systems.^[7] Pancreatitis is of two forms: acute and chronic. It was recently discovered that chronic pancreatitis is a consequence of repeated episodes of an acute case.^[8]

Plants are utilized globally as food or medicine.^[9] At least one-quarter of people with diseases worldwide use plant-derived substances as crude drugs. A survey by the World Health Organization (WHO) showed that 80 percent of Asians and Africans use herbal formulations for some aspects of primary health care.^[10, 11]

Dialium guineense (Velvet Tamarind) is a medicinal plant used in Traditional Medicine for the treatment of infectious diseases.^[12] It is a tall, tropical, fruit-bearing tree, belonging to the *Leguminosae* family, and has small, typically grape-sized edible fruits with brown hard inedible shells. In Africa, it grows in dense forests along the southern edge of the Sahel.^[13] The plant grows naturally in West African countries, Central African Republic, and Sudan. In Nigeria, it is known by different names: *Icheku* (Igbo), *Awin* (Yoruba), *Tsamiyarkurm* (Hausa) and *Amughen* (Bini).^[13] The plant is rich in important phytochemicals.^[14, 15] At present, not much is known about the adverse effect of extracts of *D. guineense* stem bark on rat pancreas. The aim of this study was to investigate the pancreatotoxicity of ethanol extract of *D. guineense* stem bark in Wistar rats.

MATERIALS AND METHODS

Chemicals

The chemicals and reagents used in this study were of analytical grade and they were bought from Sigma-Aldrich Ltd. (USA).

Plant Material

The stem barks of *D. guineense* were obtained from Auchi, Edo State, Nigeria and authenticated at the herbarium of the Department of Plant Biology and Biotechnology, University of Benin, Benin City, Nigeria (No. UBHp330).

Plant Extraction

The stem bark was washed and shade-dried at room temperature for two weeks and pulverized with a mechanical blender. Exactly 500 g of the powder was soaked in 5000 mL absolute ethanol. The resultant ethanol extract was filtered with a muslin cloth and freeze dried using a lyophilizer.^[16]

Experimental Rats

Male Wistar rats (n = 35) weighing 160– 180 g (mean weight = 170.00 ± 10.00 g) were obtained from the Department of Anatomy, University of Benin, Benin City, Nigeria. The rats were housed in metal cages under standard laboratory conditions: room temperature, 55– 65 % humidity and 12-h light/12-h dark cycle. They were allowed free access to pelletized growers mash and clean drinking water. The rats were acclimatized to the laboratory environment for one week prior to commencement of the study. Standard experimental protocol was followed for this study.

Experimental Design

The rats were randomly assigned to 7 groups (5 rats per group). One group served as control, while rats in the treatment groups received varied doses of the extract (200 - 5000 mg/kg bwt) for 28 days. Blood samples were collected before treatment and served as basal samples. At the end of the 28th day the rats were fasted overnight

and euthanized. Blood sample collected in heparin containers was centrifuged at 3000 rpm for 10 min to obtain plasma which was used for biochemical analysis.

Pancreatic Function Test

The activity of pancreatic α -amylase was measured in plasma.^[17]

Determination of Lipid Peroxidation in Rat Pancreas

Malondialdehyde (MDA) level was measured in pancreas homogenate.^[18]

Histological Examination of Rat Pancreas

Sizeable portions of the pancreas were sectioned and fixed in 10 % formalin for 48 h, and thereafter dehydrated using graded concentrations of ethanol. The specimens were cleared three times with xylene prior to embedment in paraffin. Serial sections of exactly 4 μ m thickness were stained with haematoxylin and eosin (H & E) according to standard protocol. Histopathological examination was performed under light microscopy using an image analyzer (Image Proplus, version 3.0). The specimen photomicrographs were captured at a magnification of 100.

Statistical Analysis

Data are expressed as mean ± standard error of mean (SEM, n = 5). Statistical analysis was performed using SPSS (version 20). Groups were compared using Duncan multiple range test. Statistical significance was assumed at $p < 0.05$.

RESULTS

Effect of Ethanol Extract of *D. guineense* Stem Bark on Weight Parameters

As shown in Table 1, percentage increases in body weights of rats treated with ethanol extract of *D. guineense* stem bark were significantly reduced, relative to the control group ($p < 0.05$). However, there were no significant differences in the corresponding relative pancreas weights among the groups ($p > 0.05$).

Table 1: Comparison of the Effect of Ethanol Extract of *D. guineense* Stem Bark on Weight Parameters

Groups	% Increase in weight	Relative pancreas weight ($\times 10^{-3}$)
Control	61.35 ± 4.11	4.04 ± 0.50
200 mg/kg bwt	52.60 ± 2.92 ^a	3.72 ± 0.05
500 mg/kg bwt	22.63 ± 1.56 ^{ab}	4.75 ± 0.02
1000 mg/kg bwt	21.00 ± 1.00 ^{ab}	3.78 ± 0.04
2000 mg/kg bwt	18.30 ± 1.06 ^{ab}	4.42 ± 0.11
3500 mg/kg bwt	17.73 ± 0.92 ^{ab}	3.90 ± 0.02
5000 mg/kg bwt	16.80 ± 1.10 ^{ab}	3.67 ± 0.03

Data are percentage weight increase and relative pancreas weight, and are expressed as mean ± SEM (n = 3). ^a $p < 0.05$, when compared with control group; ^b $p < 0.05$, when compared with 200 mg/kg bwt group.

Pancreatic Function in Extract-Treated Rats

Treatment with ethanol extract of *D. guineense* stem bark did not elicit any significant differences in the activities of α -amylase among the lower dose groups ($p > 0.05$), but they were significantly increased in groups VI and VII ($p < 0.05$). In all instances, the basal activities of the measured index of pancreatic function were not

significantly different from the values after treatment ($p > 0.05$). Moreover, there were no significant increases in

the concentrations of MDA in the pancreas of extract-treated rats ($p > 0.05$; Tables 2 and 3).

Table 2: Effect of Ethanol Extract of *D. guineense* Stem Bark on Pancreatic Function.

α -Amylase Activity (U/L)	Groups							
	Control	200 mg/kg bwt	500 mg/kg bwt	1000 mg/kg bwt	2000 mg/kg bwt	3500 mg/kg bwt	5000 mg/kg bwt	
B	-	46.24 \pm 4.17	18.24 \pm 1.51	58.01 \pm 2.28	17.15 \pm 0.82	60.19 \pm 2.15	64.12 \pm 3.93	
T	36.70 \pm 2.60	48.30 \pm 1.05	24.65 \pm 0.60	46.50 \pm 2.25	22.63 \pm 0.60	63.59 \pm 1.05*	66.40 \pm 2.05*	

Data are activities of α -amylase and are expressed as mean \pm SEM (n = 5). B = basal means; and T = test means. * $p < 0.05$, when compared with control group.

Table 3: Concentrations of MDA in Pancreas Homogenates.

Groups	MDA Concentration (mole/mg tissue) $\times 10^{-4}$
Control	3.53 \pm 1.72
200 mg/kg bwt	4.37 \pm 0.44
500 mg/kg bwt	3.24 \pm 0.43
1000 mg/kg bwt	3.68 \pm 0.98
2000 mg/kg bwt	5.57 \pm 0.01
3500 mg/kg bwt	5.58 \pm 0.50
5000 mg/kg bwt	5.73 \pm 0.24

Data are concentrations of pancreatic MDA and are expressed as mean \pm SEM (n = 5).

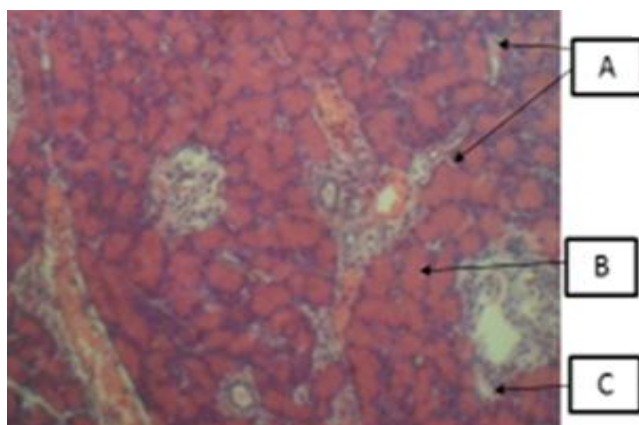


Plate 1 (Control): Rat pancreas composed of A (islets of Langerhans); B (exocrine glands); and C (interlobular connective tissue) (H & E x 100)

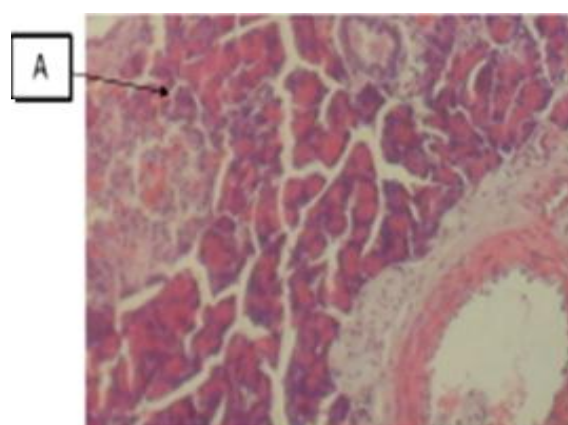


Plate 2: Rat pancreas treated with 200 mg/kg bwt ethanol extract of *D. guineense* showing A (moderate vascular dilation) (H & E x 100)

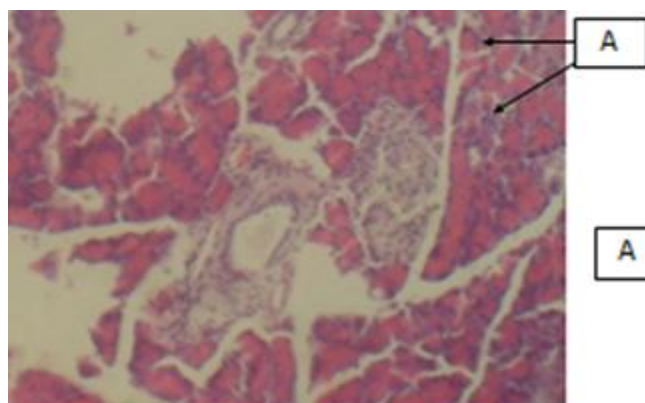


Plate 3: Rat pancreas treated with 500 mg/kg bwt ethanol extract of *D. guineense* showing A (normal pancreatic architecture) (H & E x 100)

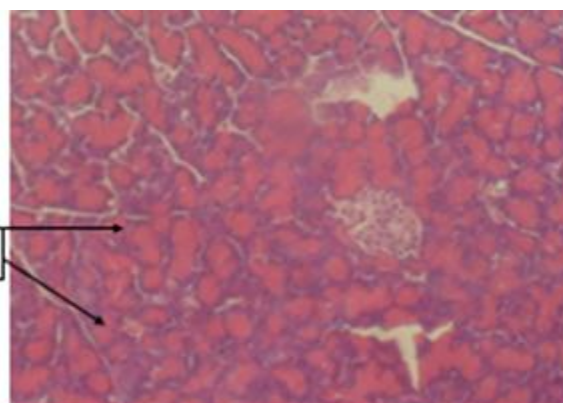


Plate 4: Rat pancreas treated with 1000 mg/kg bwt ethanol extract of *D. guineense* showing A (normal pancreatic architecture) (H & E x 100)

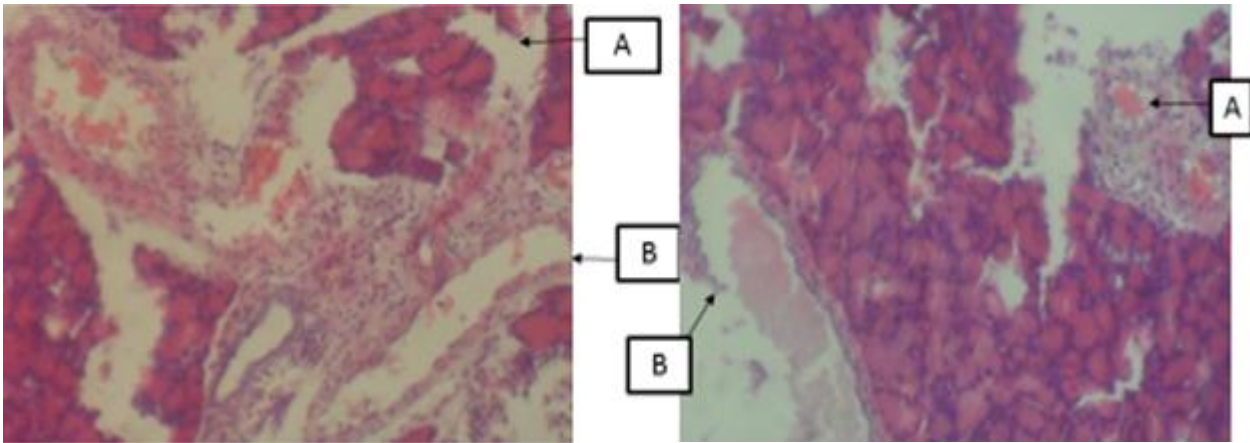


Plate 5: Rat pancreas treated with 2000 mg/kg bwt ethanol extract of *D. guineense* showing A (moderate vascular dilation) and B (ductal dilation) (H & E x 100)

Plate 6: Rat pancreas treated with 3500 mg/kg bwt ethanol extract of *D. guineense* showing A (mild vascular dilation) and B (severe ductal dilation) (H & E x 100)

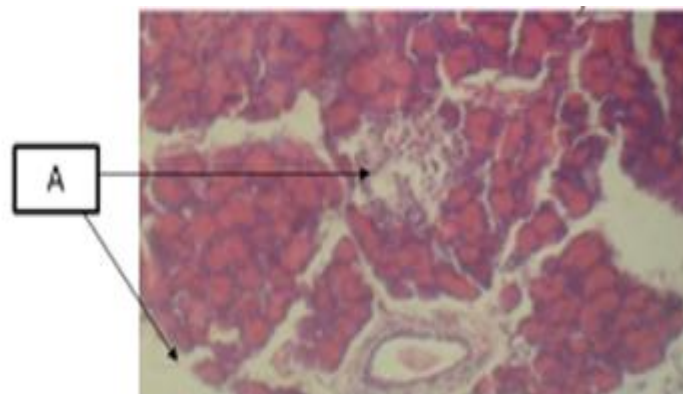


Plate 7: Rat pancreas treated with 5000 mg/kg bwt ethanol extract of *D. guineense* showing A (normal pancreatic architecture) (H & E x 100)

Figure 1: Effect of Ethanol Extract of *D. guineense* Stem Bark on the Histology of Rat Pancreas.

DISCUSSION

Pancreas, a glandular organ in the digestive and endocrine systems of vertebrates, is located in the abdominal cavity behind the stomach. As an endocrine gland it synthesizes insulin, glucagon, somatostatin, and pancreatic polypeptide which circulate freely in the blood.^[19] The pancreas is also a digestive organ, secreting pancreatic juice which contains enzymes that facilitate digestion and absorption of nutrients in the ileum. The organ is about 15 cm (6 in) long. Anatomically, the pancreas is divided into a head, which rests within the concavity of the duodenum, a body lying behind the base of the stomach, and a tail, which ends abutting the spleen. The neck of the pancreas lies between the body and head, and lies anterior to the superior mesenteric artery and vein. The head of the pancreas surrounds these two vessels, and a small uncinata process emerges from the lower part of the head, lying behind the superior mesenteric artery.^[19] The pancreas has an internal hormonal role (endocrine) and an external digestive role (exocrine). It has two major

ducts, the main pancreatic duct, and the accessory pancreatic duct, which drain enzymes through the ampulla of Vater into the duodenum.^[20] The functional state of the pancreas is evaluated via determination of the activities of α -amylase, lipase and elastase (in stool).^[20] Certain drugs have been demonstrated to cause acute pancreatitis.^[1] The role of oxidative stress in disease pathogenesis is well documented. Oxidative stress-triggered mitochondrion membrane rupture leads to pancreatic cell necrosis. Reactive oxygen species (ROS) produced within the cells rupture lysosome membrane releasing lysosome hydrolases thereby weakening zymogen granule membranes, and this in turn causes cell necrosis.^[1,3]

Pancreatotoxicity is characterized by widespread alterations of the membranous organelles of the acinar cells, especially the endoplasmic reticulum and the zymogen granules. The onset of the hemorrhagic necrosis of the pancreas is due to an endogenous, intraparenchymal activation of the zymogenic proteases,

including proelastase.^[3] In addition, there is severe congestion and edema of the stroma, which contains large quantities of extravasated red cells as well as numerous inflammatory cells, mostly neutrophils. Acute inflammation, necrosis, and areas of early calcification are seen in the abdominal fat tissues.

This study investigated the pancreatotoxicity of ethanol extract of *D. guineense* stem bark in Wistar rats. The results showed that the ethanol extract of the medicinal plant did not significantly alter the markers of pancreatic function as well as the architecture of rat pancreas throughout the period of exposure. The beneficial effects of extracts of *D. guineense* have been reported.^[21-25] In previous studies, the dose responses of extracts of the medicinal plant were reported.^[26-29]

CONCLUSION

The results obtained in this study have shown for the first time that the plant extract is not toxic to rat pancreas. However, further studies will be needed to ascertain the long-term effect of the extract on other systems in animal models.

REFERENCES

- Kaurich, T. (2008). Drug-induced acute pancreatitis. *Proc (Bayl Univ Med Cent)*, 21(1): 77–81.
- Badalov, N., Baradaran, R., Iswara, K., Li, J., Steinberg, W. and Tenner, S. (2007). Drug-induced acute pancreatitis: an evidence-based review. *Clin. Gastroenterol. Hepatol*, 5: 648–661.
- Eltookhy, A. and Pearson, N.L. (2006). Drug-induced pancreatitis. *Can Pharmacists J*, 139(6): 58–60.
- Mallick, S. (2004). Metformin induced acute pancreatitis precipitated by renal failure. *Postgrad. Med. J*, 80: 239–240.
- Schmidt, L.E. and Dalhoff, K. (2004). Hyperamylasaemia and acute pancreatitis in paracetamol poisoning. *Aliment. Pharmacol. Ther*, 20: 173–179.
- Banks, P.A. and Freeman, M.L. (2006). The Practice Guidelines in Acute Pancreatitis. *Am. J. Gastroenterol*, 101: 2379–2400.
- Dragovic, G., Milic, N. and Jevtovic, D. (2005). Incidence of acute pancreatitis and nucleoside reverse transcriptase inhibitors usage. *Int. J. STD AIDS*, 16: 427.
- Petrov, M.S. and Yadav, D. (2019). Global epidemiology and holistic prevention of pancreatitis. *Nat. Rev. Gastroenterol. Hepatol*, 16: 175–184.
- Stickel, F. and Schuppan, D. (2007). Herbal medicine in the treatment of liver diseases. *Dig Liver Dis*, 39: 293–304.
- Luper, S.A. (1998). Review of plants used in the treatment of liver disease: part one. *Altern Med Rev*, 3: 410–421.
- Thyagarajan, S.P., Jayaram, S., Gopalakrishnan, V., Hari, R., Jayakumar, P. and Sripathi, M.S. (2002). Herbal medicines for liver diseases in India. *J. Gastroenterol. Hepatol*, 17: S370–376.
- Bero, J., Ganfon, H., Jonville, M.C., Frederich, M., Gbaguidi, F., De, M.P., Moudachirou, M. and Quetin, L.J. (2009). In vitro antiplasmodial activity of plants used in Benin in traditional medicine to treat malaria. *Journal of Ethnopharmacology*, 122(3): 439–444.
- Kar, A. (2007). *Pharmacognosy and Pharmacobiotechnology (Revised-Expanded Second Edition)*. New Age International Limited Publishers, New Delhi, 332–600.
- Abu, O.D., Onoagbe, I.O. and Obahiagbon, O. (2020). Qualitative phytochemical screening and proximate analysis of *Dialium guineense* stem bark. *IAR Journal of Agriculture Research and Life Sciences*, 1(4): 108–112.
- Abu, O.D., Imafidon, K.E. and Iribhogbe M.E. (2015). Biochemical effect of aqueous leaf extract of *Icacina trichanta* Oliv. on urea, creatinine and kidney oxidative status in CCl₄-induced Wistar rats. *Nigerian Journal of Life Sciences*. 5(1): 85–89.
- Abu, O.D., Aleogho, B.M. and Omoregie F.O. (2019). Aqueous leaf extract of *Icacina trichanta* Oliv. improves lipid profile and CCl₄-induced histological changes in the liver and kidney of Wistar rats. *Asian Journal of Research in Biochemistry*, 4(1): 1–11.
- Bernfeld, P. (1955). Enzymes of starch degradation and synthesis. *Adsan. Enrs-rnoL*, 12: 379–428.
- Guttridge, J.M.C. and Wilkins, C. (1982). Cancer dependent hydroxyl radical damage to ascorbic acid. Formation of thiobarbituric acid reactive product. *FEBS Lett*, 137: 327–340.
- Drake, R.L., Vogl, W. and Tibbitts, A.W.M. (2005). *Gray's anatomy for students*. Philadelphia: Elsevier/Churchill Livingstone, Pp. 288–290, 297, 303.
- Young, B. (2006). *Wheater's functional histology: a text and colour atlas*. Churchill Livingstone/Elsevier, Pp. 299–301.
- Abu O.D. and Onoagbe I.O. (2021). Acute toxicity of aqueous and ethanol extracts of *Dialium guineense* stem bark. *Journal of Bioinnovation*, 10(2): 427–432.
- Abu, O.D., Onoagbe, I.O., and Ekugum E. (2022). Nephrotoxic Evaluation of Aqueous Stem Bark Extract of *Dialium guineense* in Normal Wistar Rats. *Journal of Pharmaceutical and Bio-Medical Sciences*, 2(9): 353–357.
- Abu, O.D., Okuo, A.V. and Osemwota, O.F. (2022). Total Saponins and Tannins of *Dialium guineense* Stem Bark Protect Against CCl₄-induced Oxidative Stress in Rats Liver. *International Journal of Medical and Clinical Case Reports*, 1(1): 15–20.
- Abu, O.D., Okuo, A.V. and Osemwota, O.F. (2022). Extracts of *Dialium guineense* Stem Bark Ameliorates CCl₄-induced Oxidative Stress in Liver of Wistar Rats. *Biomedical Journal of Scientific and Technical Research*, 46(2): 37297–37301.

25. Abu O.D., Ezike T.V. and Ajuwa O.I. (2022). Cardioprotective property of extracts of *Dialium guineense* stem bark in rats exposed to CCl₄. *American Journal of Biomedical Science and Research*, 2022: 689–693.
26. Abu, O.D., Onoagbe, I.O., and Ojo, I. (2021). Graded and quantal dose response of total tannins isolated from the stem bark of *Dialium guineense*. *Advanced Research Journal of Medicine and Clinical Science*, 08(10): 699–703.
27. Abu, O.D., Onoagbe, I.O., and Ojo, I. (2022). Dose response study of aqueous extract of *Dialium guineense* stem bark. *American Journal of Biomedical Science and Research*, 15(2): 250–252.
28. Abu, O.D., Onoagbe, I.O., and Ojo, I. (2022). Dose response of total saponins isolated from the stem bark of *Dialium guineense*. *Journal of Advances in Plant Biology*, 1(4): 1–6.
29. Abu, O.D., Onoagbe, I.O., and Ojo, I. (2021). Determination of effective dose for ethanol extract of *Dialium guineense* stem bark. *Journal of Medical Research and Case Reports*, 3(2): 1–4.