



OVARIAN FIBROMA IN A PATIENT WITH MAYER-ROKITANSKY SYNDROME: A CASE OF REPORT

Oumaima Mhamdi*, Amina Lakhdar, Aziz Baydada, Najia Zeraiidi and Aicha Kharbach

Department of Gynecology and Obstetrics, Maternity of Souissi, Faculty of Medicine and Pharmacy, Mohamed VSouissi University, Ibn Sina Hospital, Rabat, Morocco.

Corresponding Author: Dr. Oumaima Mhamdi

Department of Gynecology and Obstetrics, Maternity of Souissi, Faculty of Medicine and Pharmacy, Mohamed VSouissi University, Ibn Sina Hospital, Rabat, Morocco.

Article Received on 25/01/2021

Article Revised on 15/02/2021

Article Accepted on 08/03/2021

ABSTRACT

Mayer-Rokitansky syndrome and ovarian fibroma are two uncommon and very rare diseases. The combination of the two of them is even more exceptional. MRKH syndrome is defined by a complete or not aplasia of the uterus and the vagina in a woman with no medical history that can affects infertility but doesn't increase the risk in ovarian pathology. Here we report the case of a 39 years old woman with primary amenorrhea who was admitted for an acute pain and the MRI reveals an association between MRKH syndrome and ovarian fibroma confirmed by surgery and histological study.

KEYWORDS: Mayer-Rokitansky syndrome, MRKH syndrome, ovarian fibroma, ovarian neoplasm.

INTRODUCTION

Mayer-Rokitansky-Küster-Hauser syndrome is a rare female condition that causes a total or partial aplasia of the uterus and two thirds of the vagina with normal karyotype and ovarian function.^[1,2] Ovarian fibroma, a sex-cord stromal disorder, is an uncommon ovarian disease^[3,4] The combination of the two of them is exceptional and few sporadic cases have been reported in the literature.^[5-9]

CASE REPORT

The patient is a 39 years old woman, with a primary amenorrhea of 13 years without any other medical history. She was admitted for a brutal, acute left pelvic pain without metrorrhagia or any other symptom. The ultrasonography found a heterogeneous fluid pelvic mass with signs of torsion. We couldn't identify the uterus. MRI shows a uterine and renal aplasia with vaginal hypoplasia and a large hemorrhagic cystic mass that can be due to an adnexal torsion (figure 1).

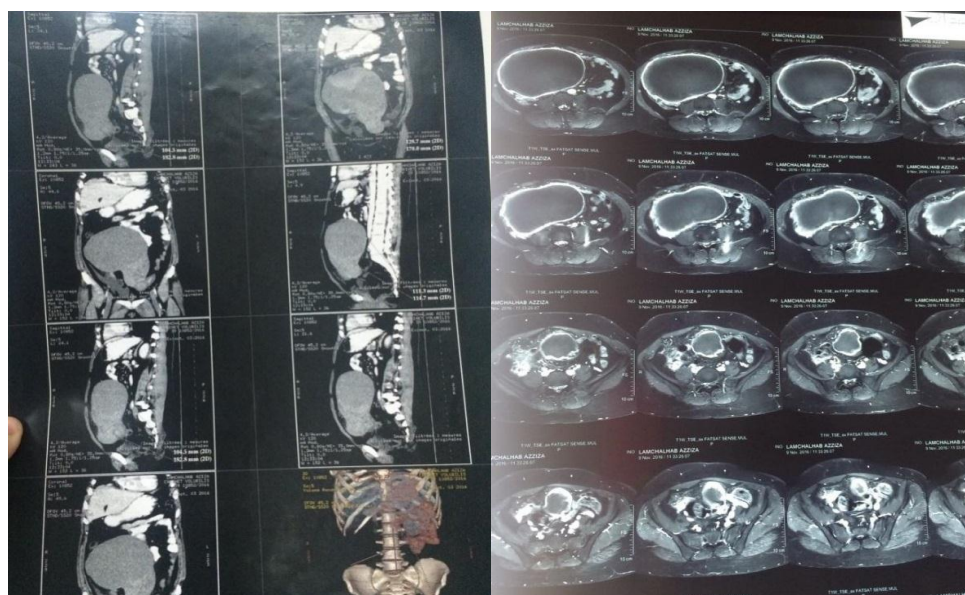


Figure 1: MRI showing both the ovarian mass and the uterus and vaginal hypoplasia.

The surgery confirmed the aplasia of the uterus and the kidney. The origin of the mass was ovarian. A conservative treatment was done with an excision of the mass (figure 2,3).

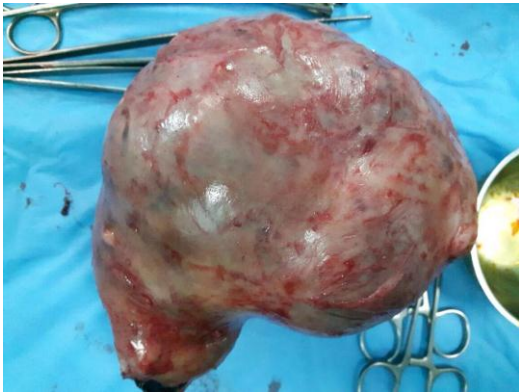

Figure 2: the ovarian mass after the conservative surgery.

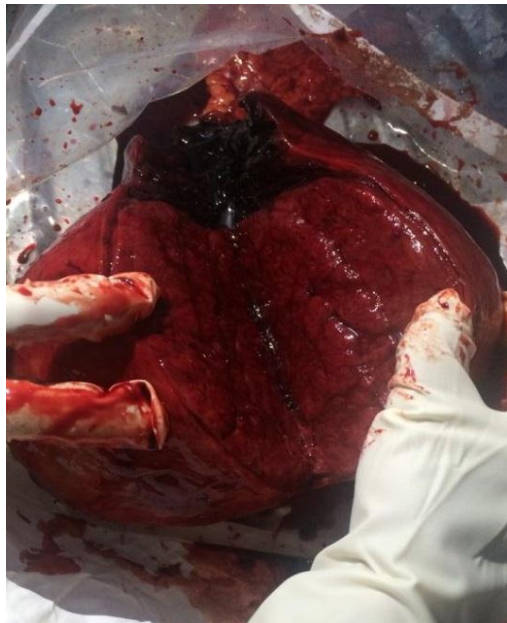

Figure 2: The fibromatous nature of the mass.

Anatomopathological study confirmed the ovarian origin and the fibromatous nature of the mass

DISCUSSION

Mayer-Rokitansky (MRKH) syndrome is a disorder that happens in females with no history in their family and affects reproductive system. It occurs on 1 per 4500 women.^[1,2] It's a genital aplasia of the uterus and the proximal two thirds of the vagina with other müllerian duct abnormalities in a woman who have a normal ovarian function, normal external genital, normal female chromosome pattern: 46,XX. In type 1, we have an isolated absence of the proximal two thirds of the vagina.^[1,2] In type 2 or MURCS (Müllerian duct aplasia, renal aplasia, cervicothoracic, somite dysplasia), we can find other malformations like vertebral or skeletal abnormalities (spinal bones in 20 to 26% of cases),

cardiac abnormalities (heart defects), upper tract urologic abnormalities in 50% (kidney abnormality formed like unilateral renal agnesis or positioned) and otologic abnormalities (hearing loss in 10 to 25% of cases). Type 2 is more frequent than type 1. MRKH syndrome is due to an incomplete development of the Müllerian duct during the fifth week of gestation. This structure in the embryo develops into the uterus, fallopian tubes, cervix, upper two thirds parts of the vagina and renal system. Ovarian function is normal because ovarian develops from the primitive ectoderm, independent of the mesoderm. The cause is unknown. Before, we thought that it was a sporadic reason but some familial cases support the hypothesis of genetic etiology. The precise gene is not identified. We only know that the transmission is autosomal dominant with incomplete penetrance and variable expressivity. The pathogenesis is then multifactorial. It's a combination between genetic and environmental factors. The environmental hypothesis assumes that MRKH syndrome is caused by different environmental factors during pregnancy like medication or maternal illness. Clinically, the aim symptom is a primary amenorrhea (it's the second cause after dysgenesis). It induces a cyclic abdominal pain due to cyclic endometrial shedding without patent drainage pathway, infertility. The ovarian function is normal. In physical examination, we have normal secondary female sexual characteristics after puberty, normal breast and pubic hair development. Height is normal. In speculum examination, the vagina can be impossible to find because of the degree of vaginal agenesia. The patient may have voiding difficulties, urinary incontinence, recurrence urinary infection, vertebral abnormalities like scoliosis. Laboratory studies, especially chromosomal analysis exclude karyotype abnormalities. Circulating levels of LH and FSH is normal. In ultrasonography, we don't find uterus. It can identify uterine duplication or tubal obstruction. It also shows kidney, bladder and vertebral abnormalities.^[1] MRI is more sensible and specific. It can diagnosis without any doubt the uterine and vaginal aplasia and the presence or not of the cervix. It also explores the spine in case of skeletal abnormalities. MRU (urography) studies reproductive and urinary system. Intravenous pyelography completes the exploration of renal structure. Laparoscopy can be use in case of a doubt in MRI or in case of laparoscopic surgery (especially neo-vaginal one). The purpose of the management is to provide the patient with a neo-vagina in order to allow sexual function and give possibility of reproduction with assisted technique and to delete uterine anlage to prevent endometriosis. Ovarian pathology is not systematically associated with MRKH syndrome.^[2]

Ovarian fibroma is the most common sex-cord stromal tumors. It's rarely associated with hormonal production. It represents 1-4.7% of all the ovarian tumors. The average age is 48 years old. 10 to 15% are superior to 10 cm and is associated with Meigs syndrome (ascites and pleural effusion that regress after fibroma excision).^[4] It's often unilateral and is located in the left one. When it

occurs, the ovarian fibroma is associated with Gorlin or Sotos syndrome. It's asymptomatic in one third cases because of the small size. Clinical is not specific. It can appear as pelvic pain or metrorrhagia. We have an absence of palpable lower abdominal mass in 50%.^[4] Acute pain may happen, like with our patient, if there is torsion of the mass. There is no invasion or metastasis. The aim differential diagnosis is ovarian tumors especially granulosa, stromal edema or cystic degeneration. In histology, macroscopically, it's a solid, spherical, lobulated, firm and encapsulated mass that look like uterine leiomyomas. Microscopically, it's composed of spindle-shaped cells with uniform, bland nuclei and scant cytoplasm, moderate cellular with abundant intercellular collagen. On ultrasonography, we have a hypochoic, solid mass with posterior acoustic shadowing. CT scan shows a well-defined, solid, homogeneous mass with delayed contrast enhancement and dynamic contrast-enhancement. MRI identifies ovarian fibroma as a solid mass that mimics malignant neoplasm. It appears as hypo intensity on T2-weighted images. It's the key of diagnosis. The dynamic contrast-enhanced MRI distinguishes ovarian fibroma from uterine leiomyomas.^[3]

There is no direct relationship between MRKH syndrome and ovarian disease and the risk of benign or malignant ovarian tumors is still no elucidated. Only 4 cases of ovarian neoplasms associated with this disease has been reported^[5-9]: ovarian cancer, endodermal sinus tumor of the ovary, immature teratoma and bilateral tumor of the ovary. That's why even if this association is not common; we have to think about it.

CONCLUSION

In Mayer-Rokitansky disease, the ovarian function is normal and there is no evidence of an increased risk of benign or malignant ovarian condition. But, the fact that some sporadic cases have been reported in the literature and our case, suggest that the reproductive system should be explore and study carefully in case of MRKH syndrome.

REFERENCES

1. Mayer-Rokitansky-Küster-Hauser syndrome. Genetics Home reference. Health conditions.
2. Mayer-Rokitansky-Küster-Hauser (MRKH) syndrome. Karine Morcel, Laure Camborieux, and Daniel Guerrier. *Orphanet J Rare Dis.*, 2007; 2: 13.
3. Ovarian fibromas: MR imaging findings with emphasis on intratumoral cyst formation. Hiroki Katoa,*, Masayuki Kanematsua,b,1,2, Hiromi Onoa,1, Ryuichiro Yanoc,1,Tatsuro Furuic,1, Ken-ichirou Morishigec,1, Yuichiro Hatanod. *European Journal of Radiology*, 2013; 82: e417– e421.
4. Ovarian-sparing local mass excision for ovarian fibroma/fibrothecoma in premenopausal women. Yeon Jean Cho a, Hee Suk Lee a, Joo Myung Kim b, Soo Yoon Lee b, Taejong Song c, Seok Ju Seong d,

- Mi-La Kim. *European Journal of Obstetrics & Gynecology and Reproductive Biology*, 2015; 185: 78–82.
5. MAYER-ROKITANSKY-KUSTER-HAUSER SYNDROME WITH A BORDERLINE OVARIAN SEROUS CYSTADENOMA: A CASE REPORT. Murat ULUKUŞ1 Mustafa ULUKUŞ Ege Nazan TAVMERGEN GÖKER2 Mustafa Coşan TEREK1 Osman ZEKİOĞLU. *Ege Tıp Dergisi*, 2002; 41(4): 255-257.
6. Mayer-Rokitansky-Küster-Hauser syndrome and ovarian cancer. Report of a case. Ghirardini G1, Magnani A. *Clin Exp Obstet Gynecol*, 1995; 22(3): 247-8.
7. Ovarian cancer and Mayer–Rokitansky–Küster–Hauser syndrome. Andreas KavallarisEmail authorKhalid H. SaitEhab Abu MararRafat Abu ShakraKlaus Diedrich. *Gynecological Surgery*, May, 2011; 8(2): 197–199.
8. Bilateral ovarian tumors in a woman with Mayer-Rokitansky-Küster-Hauser syndrome. Anna Mishina Eugen Gladun Virgil Petrovici Iraida Iakovleva. *Letters to the Editor / European Journal of Obstetrics & Gynecology and Reproductive Biology*, 2007; 131: 101–106.
9. Ovarian dysgerminoma in Mayer–Rokitansky–Küster–Hauser syndrome. Erik T. Larsen, M.D.,1 Vivien Chang-Poon, M.D.,3 Hallgrímur Benediktsson, M.D.,I D. Ian Robertson, M.D.,1,2 and Gavin C.E. Stuart, M.D.2. *Adolesc Pediatr Gynecol*, 1992; 5: 198-200.