



**EFFECT OF CADMIUM CHLORIDE (CdCl₂) ON THE GALL BLADDER OF
CLARIAS BATRACHUS (LINN. 1758)**

Beena Joshi Bhatt* and Nighat Gull

Department of Zoology, Dolphin (PG) Institute of Biomedical and Natural Sciences,
Dehradun, 248007.

Article Received on 22/01/2016

Article Revised on 12/02/2016

Article Accepted on 03/03/2016

***Corresponding Author**

Beena Joshi Bhatt

Department of Zoology,
Dolphin (PG) Institute of
Biomedical and Natural
Sciences, Dehradun,
248007.

ABSTRACT

Cadmium has various adverse effects on aquatic fauna. Fish play an integral role in the aquatic ecosystem food web and any effects that change the population structure of fish may also alter community and food web dynamics. The consumption of fish is recommended because it is a good source of omega - 3 - fatty acids, which have been associated with health benefits due to cardio - protective effect. However the

content of heavy metals such as cadmium discovered in some fishes makes it difficult to establish clearly the role of fish consumption on a healthy diet. In the present investigation *Clarias batrachus* were exposed to chronic treatment up to 30 days Cadmium chloride (0.05ppm, 0.5ppm, 1ppm) The treated *Clarias batrachus* showed anomaly in normal histology of gall bladder. Fish at 1ppm concentration showed motility after 28 days. The 0.05ppm conc. shows the deformities in the normal structures of epithelial line, muscular layer, and mucosal folds. Columnar epithelial cells get destroyed at many places due to cadmium intoxication. In the same way mucosal folds also destroyed and deformities in the muscular layer appear due to destruction of smooth muscle cells. The changes after treatment with 0.5 ppm concentration of cadmium chloride are evidence for crystallization of bile in the lumen of the gall bladder. This may be due to excess loss of water. It also shows rupturing of submucosa. While mortality was recorded in 1 ppm concentration after 28 days. Control fish slides show normal histology.

KEYWORDS: *Clarias batrachus*, Gall Bladder, Histology, Gall bladder.

INTRODUCTION

Aquatic pollution from sources like effluents from industries, power plants, untreated domestic and sewage waste etc. have adverse effects on aquatic ecosystems. Due to which the animals thriving in these water bodies are exposed to unnaturally high levels of contaminants. Evidence of toxic effect of heavy metals has been reported on fishes and population eating contaminated food (Chang, 1996). Aquatic pollution undoubtedly has direct effects on fish health and survival. Heavy metal contamination may have lethal effects on the ecological balance of recipient environment and diversity of aquatic organism (Farombi, 2007). Many heavy metals like Copper cause adverse effect on liver of fresh water cat fish (Bhatt & Maqsood, 2015). Cadmium is non-essential and toxic element for humans mainly affecting the kidneys and the skeleton. It is also carcinogenic by inhalation. Cadmium is accumulated in bone and serve as a source of exposure later in life. In the environment cadmium is toxic to plants, animals and micro-organisms. Being an element cadmium is persist it can't broken down into less toxic substances in the environment. The degree of bioavailability and potential for effects varies depending on the form of cadmium. Cadmium accumulates mainly in the kidneys and liver of vertebrates and in aquatic invertebrate and algae. The kidney is considered the critical target organ for toxicity of cadmium in humans. The main critical effect include an increased of proteins in urine as a result of proximal tubular cell damage. The severity of the effect depends on duration and magnitude of exposure.

Cadmium has various adverse effects on aquatic fauna. Fish play an integral role in the aquatic ecosystem food web and any effects that change the population structure of fish may also alter community and food web dynamics. The consumption of fish is recommended because it is a good source of omega - 3 - fatty acids, which have been associated with health benefits due to cardio - protective effect. However the content of heavy metals such as cadmium discovered in some fishes makes it difficult to establish clearly the role of fish consumption on a healthy diet. Therefore for the recent evidence of the effect of this toxic metal on fish physiological processes. Cadmium that enters aquatic environments accumulates within the bodies of aquatic organisms. The growth, osmoregulation and reproduction of fish are affected by the exposure to this metal. Cadmium obstructs numerous reproductive processes in fish such as sexual maturation, spermatogenesis, fertilization success and development of the embryonic and post embryonic stages. Cadmium in high doses induce structural and functional alterations in various vital organs including liver, kidney, gills and intestine of fishes. The fish liver plays an important and vital functions in

basic metabolism. It is the major organ of accumulation, biotransformation and excretion of contaminants in fish. The measurement of suitable biomarkers in liver becomes useful and gives an idea about health status of fish. The gall bladder stores bile and secrete it. Toxicological studies have shown that the impact of contaminants on aquatic ecosystems can be evaluated by measuring biochemical parameters in the gall bladder of the fish that respond specially to the degree and type of contamination.

Keeping in view the above points the present study therefore undertaken to describe the histopathological changes in gallbladder of the *Clarias batrachus* fish, and their effects on normal functioning of organ.

Following are the objectives of the present study

- To observe the adverse effects of cadmium chloride on gall bladder.
- To study histology of gall bladder in different concentrations of cadmium chloride.
- To study the comprasion of different concentrations slides of cadmium chloride with the controlled fish slides.

MATERIALS AND METHODS

The fresh water Indian cat fish *Clarias batrachus* was procured from the local market machi bazaar, Paltan market Dehradun, and was transferred to large plastic troughs. They were treated with 0.5% KMnO₄ solution in minutes for dermal disinfection. Then they were acclimatized for period of fortnight to laboratory condition and were fed on artificial food. The fish was killed by decapitation and the entire digestive tract was exposed through a mid-ventral incision and removed from the body. Small pieces of gall bladder after washing in phosphate buffer were fixed by immersion in Bouin's solution. After fixation, the specimens were rinsed in water, dehydrated in graded ethanol solutions (50% to absolute), cleared in xylene and embedded in paraffin. Transverse paraffin sections (5-7 μm) of each portion of the liver were prepared and processed for staining through haematoxylin and eosin (H&E). Photomicrographs were taken with a video camera connected to microscope (Olympus, Tokyo, Japan).

RESULTS AND DISCUSSION

Normal Anatomy

Gallbladder is a pear shaped sac like structure for bile storage. It is a storage vessel for liver bile. It acts as a reservoir for holding bile on its way from the liver to the intestine. Its size

depends on the volume of bile. Wall of the gallbladder is normally 1-2 mm thick. It plays an important role in digestion. There are a few studies which suggest that bile serves similar functions in fishes. Several studies identified micro- droplets of lipid in midgut epithelium of fishes and re-absorption of water in gall bladder of fishes as in mammals. The presence of green mucus in the lumen of the atrophied gut of spawning salmon suggested bile is continuously produced in fishes. There appears to be no studies in contraction or other mechanisms controlling the release of bile during digestion from gall bladder of fish. Bile serves a number of functions, as it (a) helps in emulsification and absorption of lipids/fats, (b) neutralizes hydrochloric acid from stomach (and so prevents possible ulceration of the intestine) and (c) ensures that absorbed toxins are returned to the intestine for excretion. The size and fullness of the gall bladder is indicative of feeding status in fish. A large, distended bladder indicates that the fish has not eaten for some time whilst an empty flaccid bladder indicates that the fish has recently eaten a meal. Bile is excreted from the bladder to the intestine via the bile duct (Singh *et al.* 2005 & Susan *et al.* 2010).

Histological Changes

Fig. 1 shows (control) the normal histological structures of gall bladder constitutes muscular layer (M), submucosa (SM), muscular folds (MF) and epithelium(E) constituted of columnar epithelial cells, and the central part of gall bladder the lumen (Lu) (10 X 10). Fig. 2 (0.05ppm conc.) shows the deformities in the normal structures of epithelial line, muscular layer, and mucosal folds. Columnar epithelial cells get destroyed at many places due to cadmium intoxication. In the same way mucosal folds also destroyed and deformities in the muscular layer appear due to destruction of smooth muscle cells (10 X10). The changes after treatment with 0.5 ppm concentration of cadmium chloride are evidence for crystallization of bile in the lumen of the gall bladder. This may be due to excess loss of water (10 X10) as clear in Fig. 3. It also shows rupturing of submucosa. Mortality was recorded in 1 ppm concentration after 28 days.

During the present study the control fish gall bladder shows normal structure and test fishes show anomaly in their histology. Similar results were obtained by Katti and Sathynesen (1984), they worked on *Clarias batrachus*. They also reported that Cd- exposure lowered lipid content Nakagawa *et al.* 1979; Waku *et al.* 1980; Rana *et al.* 1980 & 1981 obtained similar results. In 1994, Rathore and Naik found same results. They investigated Cd-exposure might have lowered lipid metabolism hence less bile was utilized and good amount was

accumulated which resulted in swollen gall bladder. During the present study 0.05ppm conc.shows the deformities in the normal structures of epithelial line, muscular layer, and mucosal folds. Columnar epithelial cells get destroyed at many places due to cadmium intoxication. In the same way mucosal folds also destroyed and deformities in the muscular layer appear due to destruction of smooth muscle cells. The changes after treatment with 0.5 ppm concentration of cadmium chloride are evidence for crystallization of bile in the lumen of the gall bladder. This may be due to excess loss of water. It also shows rupturing of submucosa. These results are comparable with the results of Tripathi *et al.* 2012. They reported high concentration of Cadmium causes formation of bile crystals due to loss of water and in low concentration it shows anomaly in normal histology.

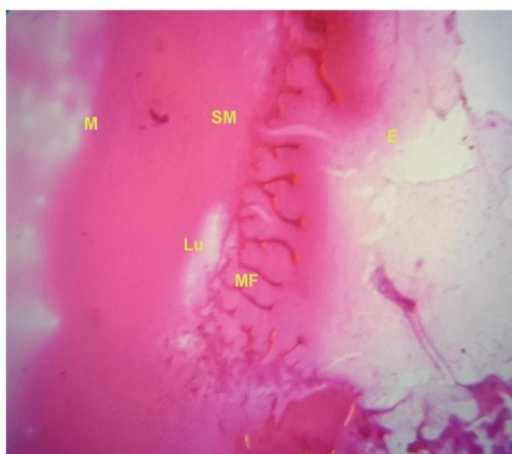


Fig. 1: Slide of Gall Bladder of Control Fish Showing Normal histology (10X10) (M: Muscular Layer, SM: Sub Mucosa, E: Epithelium, Lu: Lumen & MF: Mucosal Folds).

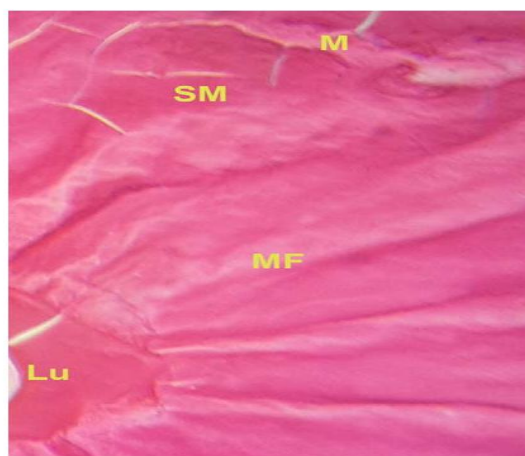


Fig. 2: Slide of Gall Bladder of fish of 0.05 ppm Concentration Showing Loosing of Muscular Layer and Rupturing of Mucosal Folds (M: Muscular Layer, SM: SubMucosa, E: Epithelium, Lu: Lumen & MF: Mucosal Folds).

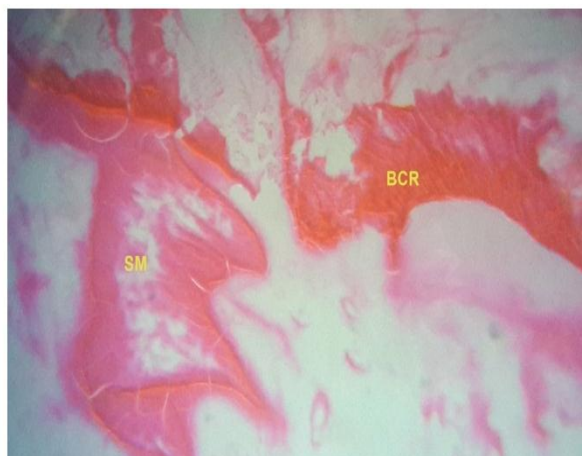


Fig. 3: Slide of Fish at 0.5 Concentration Showing Rupturing of Submucosa & Bile Crystals Due to Loss of Water (10X10) (SM: Submucosa & BCR: Bile Crystals).

CONCLUSION

Thus the present study revealed that cadmium chloride (CdCl_2) exposure induced histological changes and crystallization of bile in the lumen of gall bladder in *Clarias batrachus* (Linn. 1758).

ACKNOWLEDGEMENTS

The authors are grateful to Principal, Director and management of the Dolphin (PG) Institute of Biomedical & Natural Sciences, Dehradun for providing necessary facilities.

REFERENCES

1. Chang LW, Toxicology of metals. CRC press Inc. Lewis Publishers, 1996; New York, USA.
2. Farombi EO, Adelowo and Arioso. International Journal of Environmental Research and Public Health, 2007; 4: 158-165.
3. Bhatt BJ, Maqsood S. Int J Pharm Bio Sci., 2015; 6(2): 237 – 243.
4. Katti, SR, Sathyanesan AG. Bull. Environ. Contam. Toxicol, 1984; 32: 486-490.
5. Nakagawa MM, Takumura, Kojima S. J. Biochem., 1979; 81: 1011-1016.
6. Waku KF, Hykawa Y, Nakazawa, Arch. Biochem. Biophys, 1980; 204: 288-293.
7. Rana SV, Kumar A, Bhardwag NG. Acta Anat, 1980; 108: 402-412.
8. Rana SV, Kumar A, Bhardwag NG. Arch. Hyg. Rad. Tokiskol., 1981; 32: 157-161.
9. Rathore HS, Naik BK. Biologia, 1994; 40(1&2): 1-4.
10. Tripathi M, Mishra RP, Girtoniya V. Journal of Fisheries and Aquaculture, 2012; 3(2): 44-46.