

CASE PRESENTATION

Dr. Sami Alnajjar, Dr. Najia Al Hojaili, Dr. Attia Al Zahrani, Dr. Laila Alabasi, Dr. Sahar Ali, Dr. Hamid Mansour and Dr. Mohammad Al Thobiti

Saudi Arabia.

*Corresponding Author: Dr. Najia Al Hojaili

Saudi Arabia.

Article Received on 13/01/2019

Article Revised on 03/02/2019

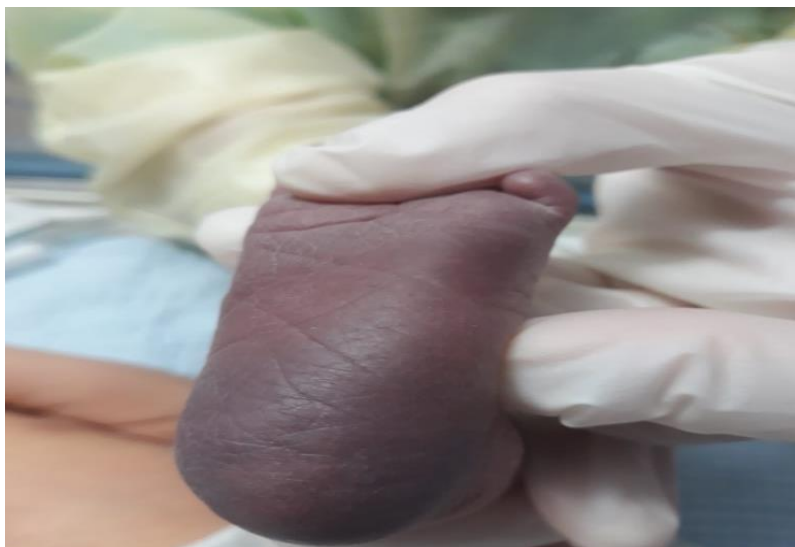Article Accepted on 24/02/2019

ABSTRACT

- **File number:-** 236888
- **Date of birth :-** 24/6/1439
- **Full term male** – 2.5 kg – to G6P4+1 uneventful pregnancy, product of C.S in **Alahli Al Saudi hosp.** because of bad CTG and fetal distress MSAF, delivered sleepy required only tactile stimulation then picked up
- **A/S:-** 5/1min 8/5min.
- **Admitted** in NICU and kept in NPO, IVF, IV antibiotic.
- **All investigation** were within normal Bl. gas normal – CXR clear lung field.
- **On 2nd day of life** developed convulsion in form of blinking of eyes, frothy oral secretion, with desaturation so loaded by phenytoin, baby was stable maintain saturation on oxyhood 3L/min.
- They sent **fax** to **MCH** for further investigation and anti-convulsion therapy.

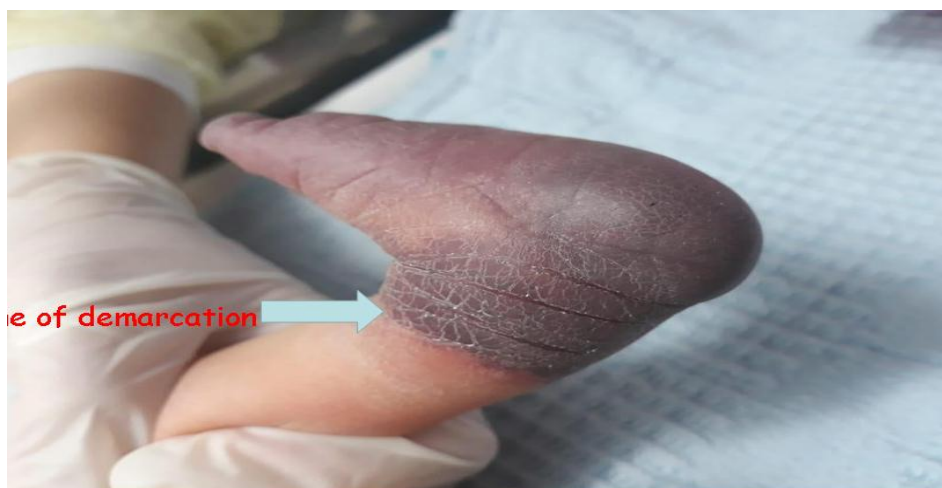
What is your Diagnosis?

- **Hypoxic ischemic encephalopathy**
- **transient metabolic disturbances**
- **Focal ischemic injury (arterial infarction – venous infarction)**
- **Intra cranial Hge**
- **Infection (congenital infection, meningitis, septicemia)**
- **Inborn error of metabolism (pyridoxine dependency, glycine encephalopathy, maple syrup urine disease)**
- **Brain anomaly**
- **Epileptic syndromes (benign familial neonatal seizures, benign idiopathic neonatal seizures)**
- **Maternal drug withdrawal**
- **Kernicterus**
- **On 3rd day of life** baby came to ER after discharge from the other hospital
- **Baby** was admitted as a case of neonatal seizure with fever for investigation full sepsis work up done started amika-vanco CT was requested to be done in the morning
- **On 4th day of life**
- **LP :-** WBC 1320 **poly** 57.3% **mono** 42.7% (D/C amika, start cefotaxime) **Glucose** 0.5 **Protein** 183 **RBCs** 5000
- **CBC and chemistry** were acceptable
- **Brain ultrasound** was done in the morning :showed large left cerebral parenchymal Hge with normal size lat ventricle and no midline shift
- **CT was done:-** multi- focal left hemispheric acute cerebral Hge and a focal hypoattenuating area in left aspect of the brain stem for clinical correlation.
- **1.30 pm**, baby developed cyanosis of the left foot and ankle (order to put hot fomentation and observe).

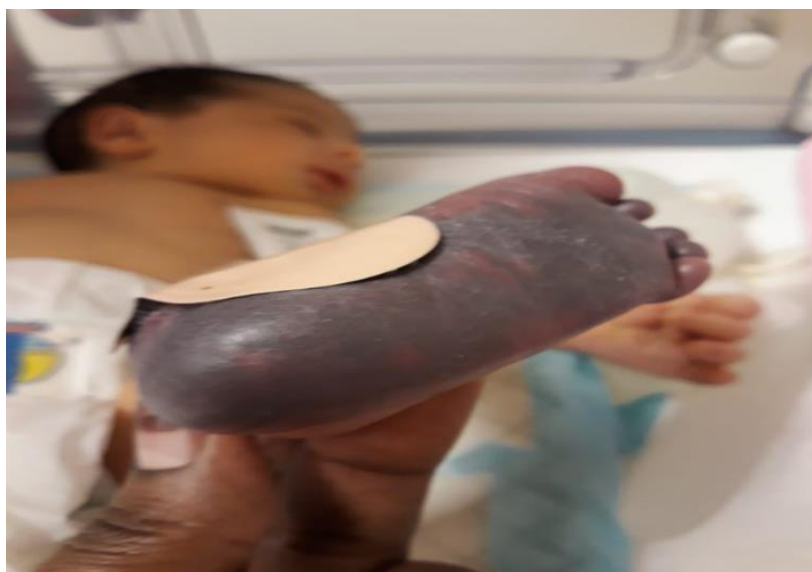

By around 4.00 pm cyanosis increased and there was line of demarcation – edema - order to shift the baby to NICU2 and urgent Doppler ultrasound – surgical

consultation – hematology consultation - vascular surgery consultation



1. **Urgent Doppler ultrasound** :- normal wave of DPA, PTA and popliteal artery
2. **Surgical consultation**:- start hot compresses – line of demarcation to be observed - no surgical intervention indicated
3. **Vascular consultation**:- left foot area red and blue – no definite history of canulation or pricking – discoloration of the whole foot – triphasic Doppler signals of DPA and PTA left side Swelling of left foot? Compartment S – recommendation baby has good vascularity of left foot limb elevation – no vascular surgery intervention
4. **Hematology consultation**:- conservative management like warm fomentation and put nitroglycerine patch.



Cefotaxime was D/C and started meropenam, ID consultation done they ordered for meropenam 10 days and vanco for 5 days

A **discussion** between our COD and hematology consultant resulted in to give FFP after taking sample for protein C, S and factor XIII

On the next 2 days there was some sort of improvement in the color of the foot and there was no need to start heparin

- **On the 7th day** baby was irritable and in pain full examination was done and there was Lt testis swelling , hard painful in touch
- **Urgent Doppler ultrasound** done showed Rt testis normal size , echogenicity and blood supply
- while Lt testis enlarged in size 9x9 mm mixed echogenicity with only venous BI supply.
- **no arterial** vascularity detected, suggesting testicular torsion
- **Urgent** pedia-surgery consultation was done and baby went to OR
- There was no **torsion thrombosis**
- Gangrenous Lt testis, part of it sluphed during manipulation and sent to histopathology

Immature testicular tissue with hemorrhagic infarction

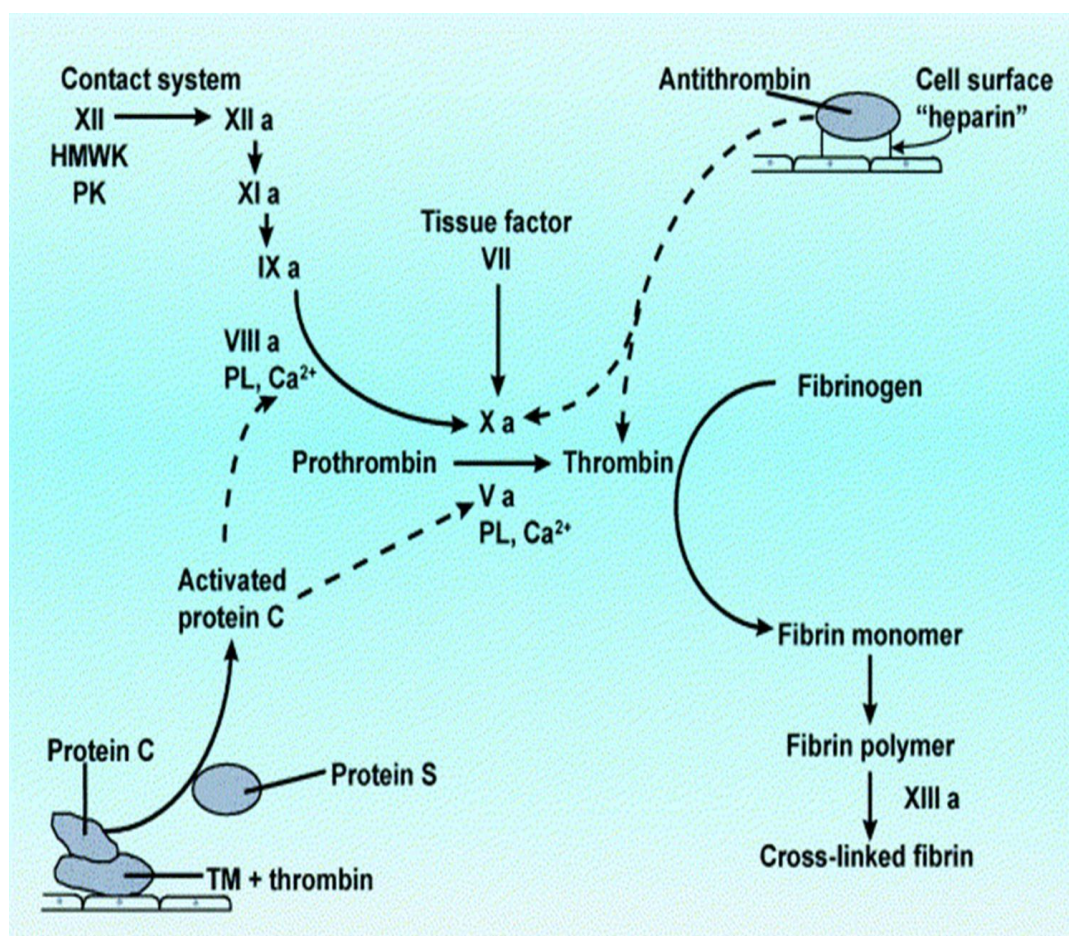
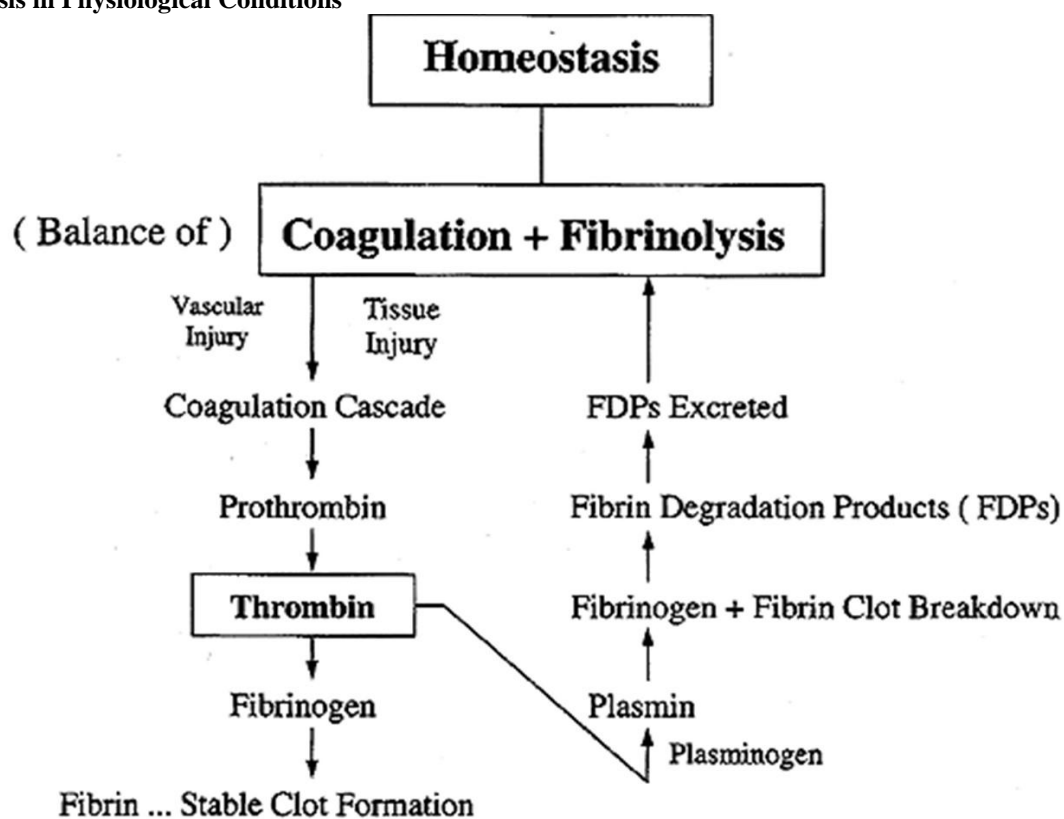
- **On the 10th day** factor V Leiden, VIII, homocysteine level
- **CT angio** was requested showed Lt intra cerebral hemorrhagic infarction with normal cerebral vein and sinuses no sign of venous thrombosis seen
- **Factor XIII** within normal levels
- **Anti-thrombin III** within normal levels
- **Factor V leiden** within normal levels
- **Factor VIII** within normal levels
- **Homocysteine level** within normal levels
- **Protein S activity**
- **Protein C activity**

- **Baby was discharged** at 19 day old, hemodynamic stable to follow up

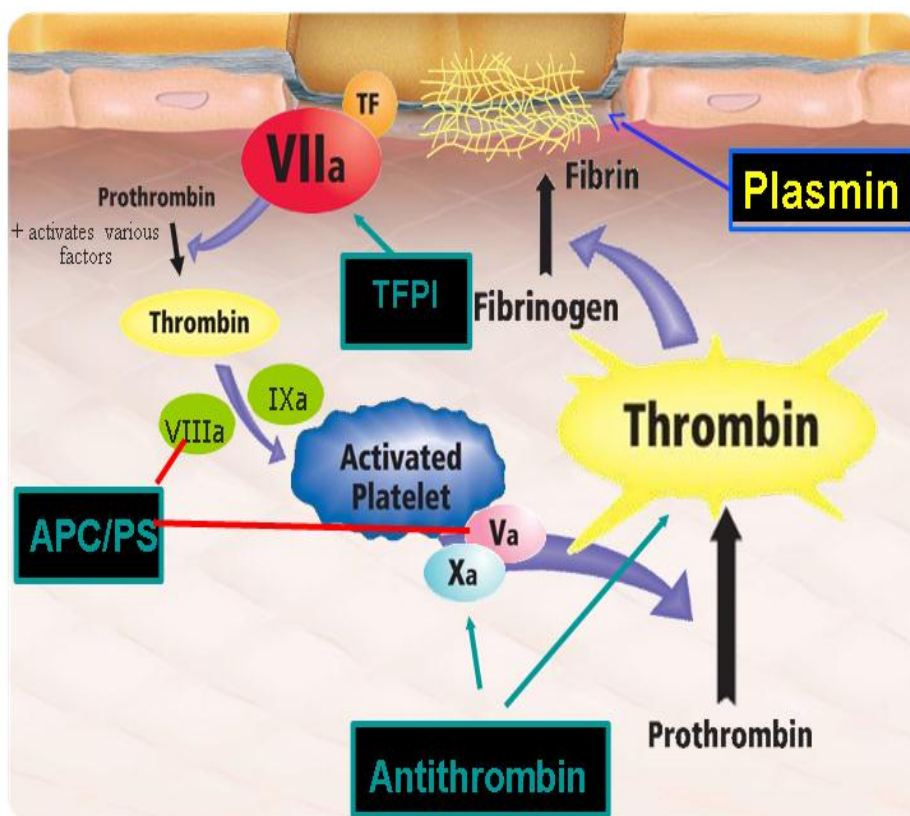
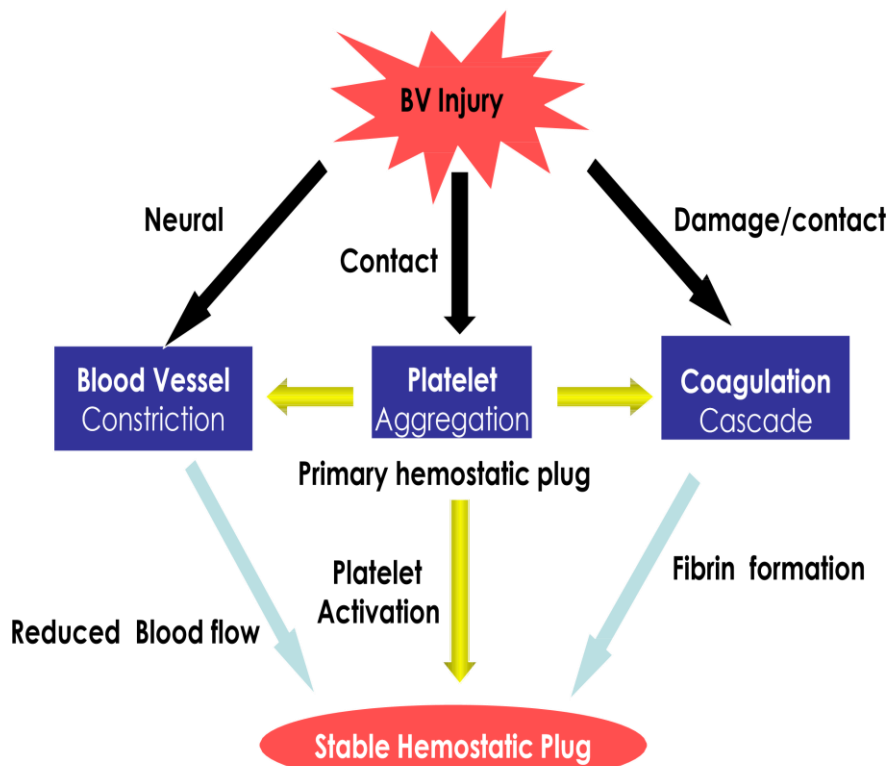
Introduction

- Protein C deficiency is a congenital or acquired condition that leads to increased risk for thrombosis.
- Congenital protein C deficiency is one of several inherited thrombophilias, which are a heterogeneous group of genetic disorders associated with an elevated risk of venous thromboembolism.

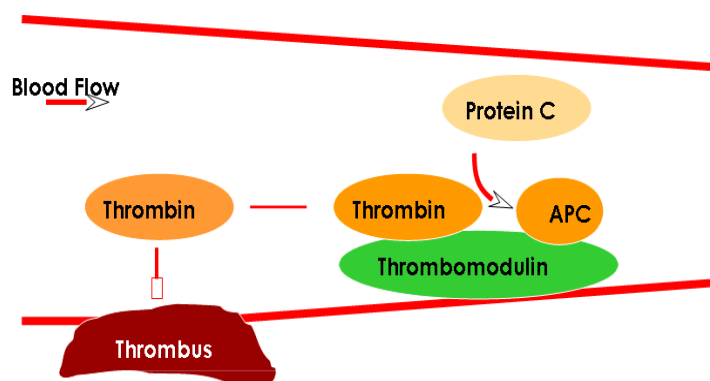
Hemostasis in Physiological Conditions



Hemostasis



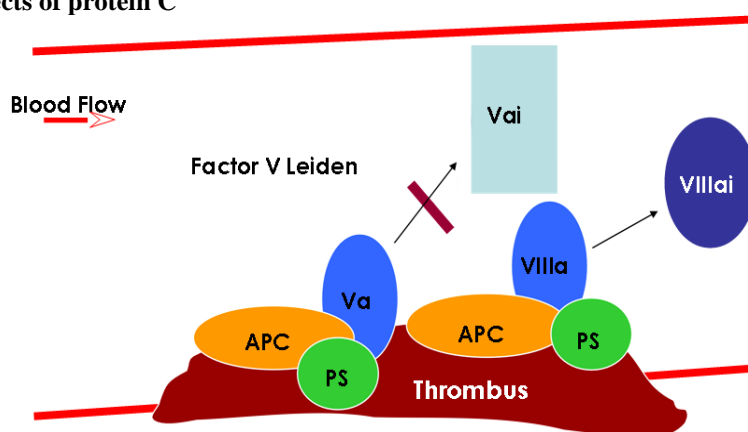
Anticoagulant protein C pathway



Anticoagulant effect at

Thrombosis Occurring the downstream damage at the vascular injury.

The anticoagulant effects of protein C



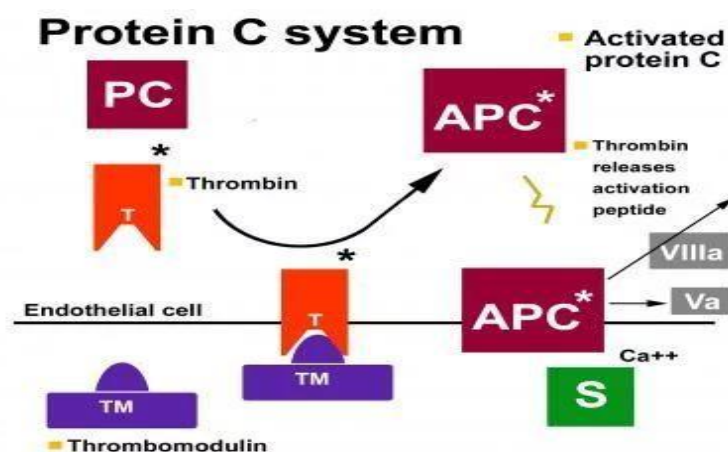
Protein C System - 3 abnormalities

- Protein C deficiency
- Protein S deficiency
 - Mutation of factor V cleavage site (activated protein C resistance)

- Rare severe homozygous - purpura fulminans
- Activity levels **50%** of normal
- Increased risk of **venous thrombosis**

Hereditary Protein C deficiency

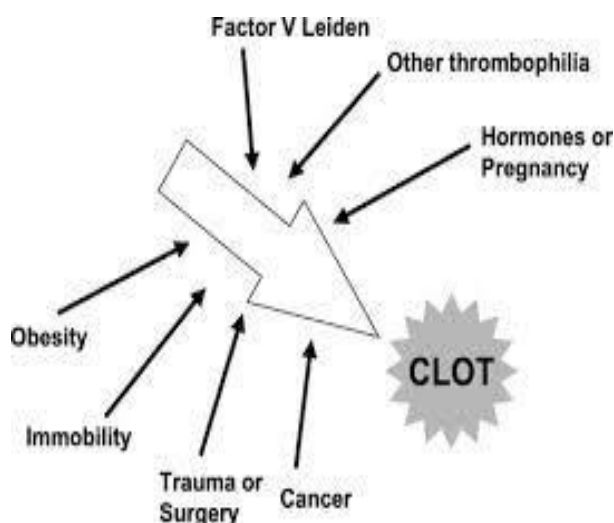
- AD
- Most patients heterozygous



The protein C pathway. APC = activated protein C; PC = protein C; S = protein S; T = thrombin; TM = thrombomodulin; Va = factor Va; VIII = factor VIIIa.

APC Resistance - Mutant Factor V (Factor V Leiden)

- **Activated Protein C (APC)** destroys factor **Va** by cleaving it at arginine 506
- Some patients have a **mutated factor V** with a glutamine at position 506, this prevents APC from cleaving factor Va and destroying it
- Defect is termed **Factor V Leiden** or **APC resistance**
- Increased risk of **venous thrombosis**



Epidemiology incidence

- In the United States and worldwide, **protein C** deficiency by plasma level alone is found in 1 in 200 to 1 in 500 persons in the general population.
- Severe **homozygous** or compound heterozygous protein C deficiency occurs in approximately 1 in 500,000 to 1 in 750,000 live births.

Clinical Presentation

Physical:- Patients with symptomatic hereditary protein C deficiency may present with **VTE** or **WISN**.

Homozygotes and compound heterozygotes frequently present with NPF during the first hours of life.

Venous thromboembolism

- Deep venous thrombosis of the lower extremity.
- A chronic condition associated with swelling, pain, discoloration, and venous insufficiency of the lower extremity.

Clinical Presentation cont

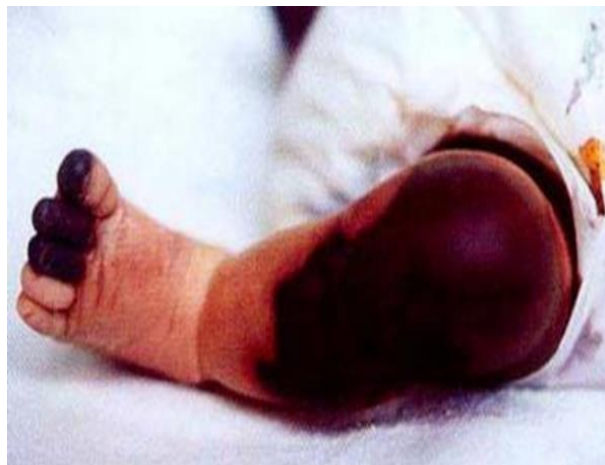Warfarin-induced skin necrosis

- The skin lesions of **WISN** occur on the extremities, torso, breasts, and penis.
- They begin as **erythematous macules** and, if appropriate therapy is not initiated promptly, evolve to become purpuric and necrotic bullae.

Clinical Presentation cont...

Neonatal purpura fulminans

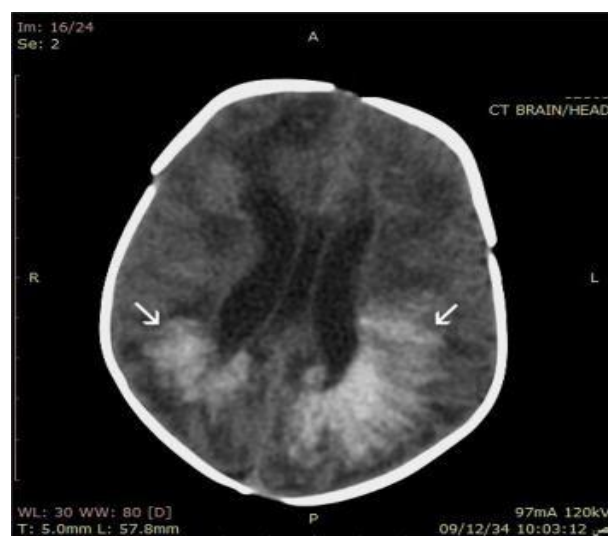- Affected neonates present with diffuse ecchymoses which, similar to the lesions of **WISN**, progress to form necrotic bullae if appropriate therapy is not rapidly instituted.



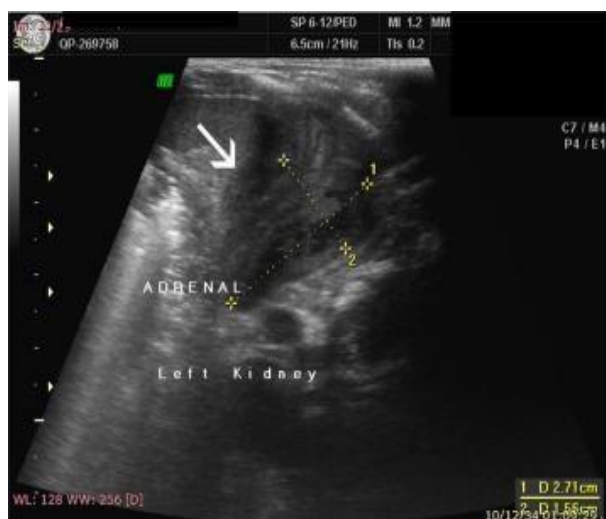A patient with neonatal purpura fulminans.

Clinical Presentation cont

- May be presented by intracranial Hge



Unenhanced axial brain CT scan shows bilateral cortical and subcortical hyperattenuating lesions indicating haemorrhage (arrows). Or bilateral adrenal Hge



Ultrasound showing that the left adrenal gland was enlarged and heterogeneous, consistent with a left adrenal haematoma (arrow) measuring 35.1 mm × 24.4 mm.

DDx

Congenital & Acquired hypercoagulable states.

	Congenital		Acquired
1.	Protein C deficiency	1.	Antiphospholipid antibody syndrome
2.	Protein S deficiency	2.	Malignancy
3.	Antithrombin III deficiency	3.	Surgery / Trauma
4.	Factor V Leiden	4.	Liver disease
5.	Prothrombin gene G20210A mutation	5.	Vit K deficiency
6.	Hyper-homocysteinemia	6.	DIC
7.	Dysfibrinolysis	7.	Severe sepsis specially Gm -ve

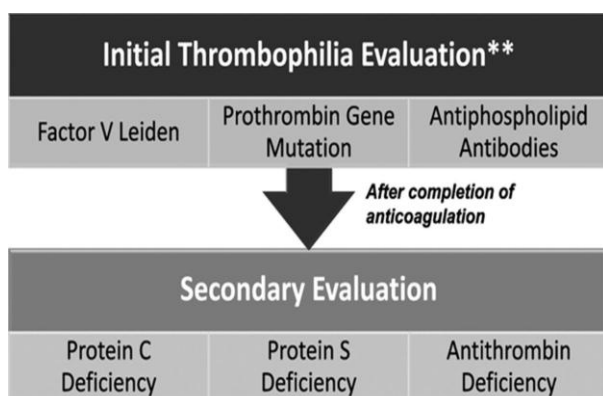
Diagnosis

- **In fact**, testing for an inherited hypercoagulable state is costly & likely to uncover an abnormality in more than **60%** of patients presenting with idiopathic VTEs.
- **Although**, the remaining **40%** will have unremarkable test results, this does not imply a true absence of a hypercoagulable state.

Gregory Piazza Circulation. 2014; 130: 283-287

Copyright © American Heart Association, Inc. All rights reserved.

A stepwise approach to thrombophilia testing



**Can be drawn in the setting of acute thrombosis or anticoagulation.

Workup**Assays**

- A variety of immunologic and functional **protein C** assays are available.

Immunologic assays

- Immunologic methods for the measurement of **protein C** antigen include enzyme-linked immunosorbent assays (ELISAs), radioimmunoassays (RIAs), and electroimmunoassays.

Functional assays

- Activated **protein C** (aPC) activity can be measured by means of a clotting assay or a chromogenic substrate. The adult reference range for protein C activity tends to be slightly lower than the immunologic normal range.

Workup cont**Screening**

The timing of testing with respect to acute thrombosis and warfarin therapy deserves special mention.

Acute thrombosis

- The levels of **protein C**, protein S, and antithrombin are reduced in the setting of acute thrombosis. Therefore, these levels should generally not be assessed at the time of presentation with acute VTE. However, a normal **protein C** activity in this setting essentially rules out hereditary **protein C** deficiency.

Warfarin

- Because **protein C** is a vitamin K–dependent protein, its levels are reduced with warfarin administration.
- Therefore, it is recommended that **protein C** testing not be performed unless the patient has been off vitamin K antagonist therapy for at least 2 weeks. If the patient has a severe thrombotic diathesis that does not permit discontinuation of anticoagulation.

Treatment

- A **substantial** proportion of individuals with **protein C** deficiency remain asymptomatic throughout life and require no specific therapy.
- However, **thromboprophylaxis** may be considered in such individuals, particularly if there is a strong family history of thrombosis

Treatment

- A **case report** by Milleret and colleagues describes 2 years of successful prophylaxis in a patient with neonatal severe protein C deficiency, using warfarin oral suspension. The international normalized ratio (INR) was measured by home monitoring, with a target INR of 2.5 to 3.5.
- **For those patients** who do develop clinical manifestations of hereditary protein C deficiency,

treatment depends on the particular clinical syndrome: venous thromboembolism (VTE), warfarin-induced skin necrosis (WISN), or neonatal purpura fulminans (NPF).

Treatment**Venous thromboembolism**

- **VTE** in patients with **protein C** deficiency is managed in much the same way as it is for patients with **VTE** due to other causes,
- Because the risk of recurrent **VTE** in **protein C** – deficient patients may be as high as 60%, long-term anticoagulation is often recommended, particularly following a spontaneous thromboembolic event.

Treatment**Warfarin-induced skin necrosis**

- **WISN** is a medical emergency that requires treatment as soon as it is recognized.
- Therapy consists of immediate discontinuation of warfarin, administration of vitamin K, and initiation of therapeutic doses of heparin.
 - If the patient is **protein C** deficient, exogenous **protein C** should be administered, either in the form of fresh frozen plasma (FFP) or, preferably, as purified **protein C** concentrate (Ceprotin). Treatment

Neonatal purpura fulminans

- Like **WISN**, **NPF** is a medical emergency that requires rapid normalization of plasma **protein C** activity. Although fresh frozen plasma has been used as a source of exogenous **protein C** in the treatment of **NPF**, frequent administration is required to maintain adequate plasma levels, thereby limiting its usefulness in this setting.
- Highly purified **protein C** concentrate (Ceprotin) represents an attractive alternative that does not subject patients to the high volume and protein load of fresh frozen plasma.

Treatment**Neonatal purpura fulminans cont**

- After treatment of the acute phase of **NPF**, patients are transitioned to anticoagulation therapy, on which they must remain indefinitely. Warfarin may be used in this setting, provided that exogenous **protein C** is administered during its initiation in order to avoid the development of **WISN**. For patients with breakthrough thrombosis despite anticoagulation.
- Living donor liver transplantations have been successfully performed in **NPF**, resulting in a permanent cure.

Treatment

- **Heparin**
- **Enoxaparin (Lovenox)**
- **Dalteparin (Fragmin)**
- **Warfarin**
- **Protein C concentrate (Ceprotin)**
- **Fresh frozen plasma**

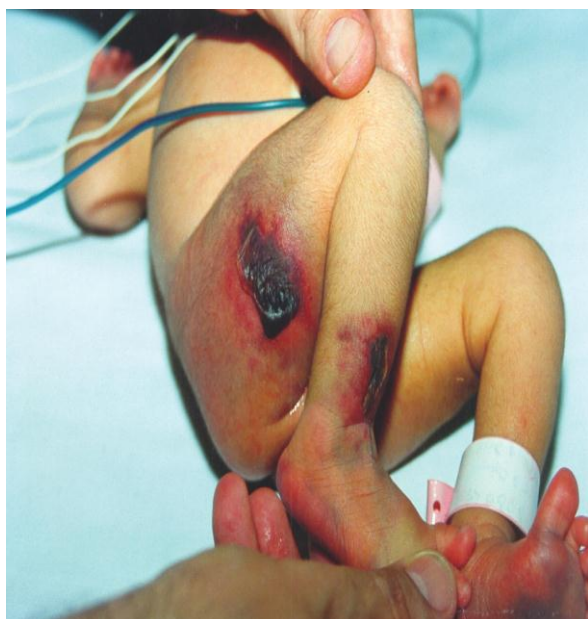

Figure 1a: Five-day-old newborn with homozygous protein C deficiency and purpura fulminans. Irregularly formed hypoperfused or necrotic skin lesions surrounded by an inflammatory border.

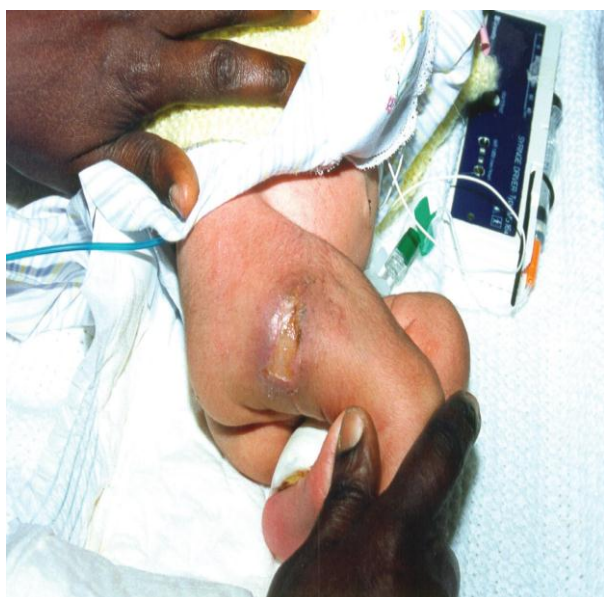

Figure 1b: The same child 6 days after beginning of protein C replacement with Ceprotin®.

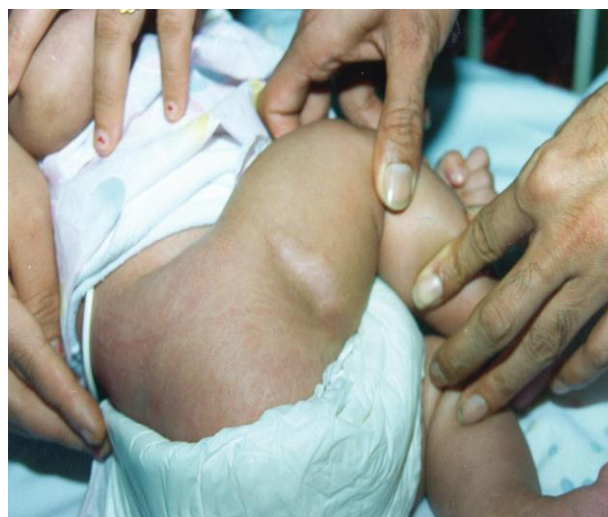

Figure 1c: The same child 2 months later. All figures from Dreyfus M, Masterson M, David M, et al 1995. Replacement therapy with a monoclonal antibody purified protein C concentrate in newborns with severe congenital protein C deficiency.

Medication

Ceprotin®

- Ceprotin® is a highly purified plasma-derived concentrate of human **protein C** zymogen
- Early case reports on the treatment of newborns with severe **protein C** deficiency and neonatal purpura fulminans demonstrated an impressive response to substitution therapy with **protein C** concentrates

Medication

Protexel®

- Protexel® (LFB, Les Ulis, France) is a **protein C** zymogen concentrate, derived from human plasma (Radosevich et al 2003).

Medication

Drotrecogin alpha activated (Xigris®)

- Drotrecogin alpha (activated) (Xigris®, Eli Lilly Co.) is available as is a recombinant analogue to the physiologic human activated **protein C**.
 - A report was published by a Japanese group, who used another concentrate of activated **protein C** to treat a female newborn who developed purpura fulminans on the third day after birth due to homozygous protein C deficiency (Nakayama et al 2000).

REFERENCES

1. Hypercoagulability syndromes: Arch intern med, 2001; 161.
2. Genetic susceptibility to venous thrombosis: N Engl J Med, 2001; 344(16).
3. Management of venous thromboembolism: N Engl J Med, December 12, 1996.
4. Goldman: Cecil textbook of medicine, 21st ed. Chapter, 187.

5. Robbins pathologic basis of disease, sixth ed. Chapter, 5.
6. Sultan A. Jafarri et al, Journal of Dermatology & Dermatologic Surgery 21 104–106 Department of Pathology, King Fahad Central Hospital, Jizan, Saudi Arabia, 2017.
7. Adam Cuker, MD, MS Assistant Professor of Medicine, Assistant Professor of Pathology and Laboratory Medicine, Perelman School of Medicine at the University of Pennsylvania, September 14, 2018.
8. Paul N Knoebl, Department of Medicine 1, Division Hematology and Hemostasis, Medical University of Vienna, Vienna, Austria.