



**AVIAN RESPIRATORY ANATOMY AND PHYSIOLOGY WITH ITS
INTERSPECIES VARIATIONS: A REVIEW**

**Arvind Kumar Pandey¹, Praveen Kumar Praveen², Subha Ganguly^{3*},
Parveez Ahmad Para⁴, Rajesh Wakchaure⁵, Saroj⁶ and Tanvi Mahajan⁷**

¹Assistant Professor, Department of Veterinary Physiology and Biochemistry, ²Assistant Professor, Department of Veterinary Public Health and Epidemiology, ³Associate Professor and Head, Department of Veterinary Microbiology, ⁴Assistant Professor, Department of Livestock Products Technology, ⁵Associate Professor, Department of Animal Genetics & Breeding, ⁶Assistant Professor, Department of Animal Nutrition, ⁷Assistant Professor, Department of Veterinary Anatomy & Histology, Arawali Veterinary College (Affiliated with Rajasthan University of Veterinary and Animal Sciences, Bikaner), V.P.O. Bajor, Dist. Sikar, Pin – 332001, Rajasthan, India.

Article Received on 20/07/2015

Article Revised on 12/08/2015

Article Accepted on 05/09/2015

***Correspondence for
Author**

Dr. Subha Ganguly

Associate Professor and
Head, Department of
Veterinary Microbiology,
Arawali Veterinary College
(Affiliated with Rajasthan
University of Veterinary
and Animal Sciences,
Bikaner), V.P.O. Bajor,
Dist. Sikar, Pin – 332001,
Rajasthan, India.

ABSTRACT

The avian respiratory system is peculiar in many aspects, especially in comparison to the mammalian species. The present review discusses in its various anatomical dispositions in the birds with its respective physiological diversity.

KEYWORDS: Avian respiratory system, Physiology.

INTRODUCTION

Some of the prominent features in avian respiratory system are as follows:

1. Presence of air sacs

Birds have lungs, but they also have air sacs. Depending upon the species, the bird has seven or nine air sacs. The air sacs include:

Two posterior thoracic

Two abdominal

Two anterior thoracic

Two cervical (these are not present in some species)

One interclavicular

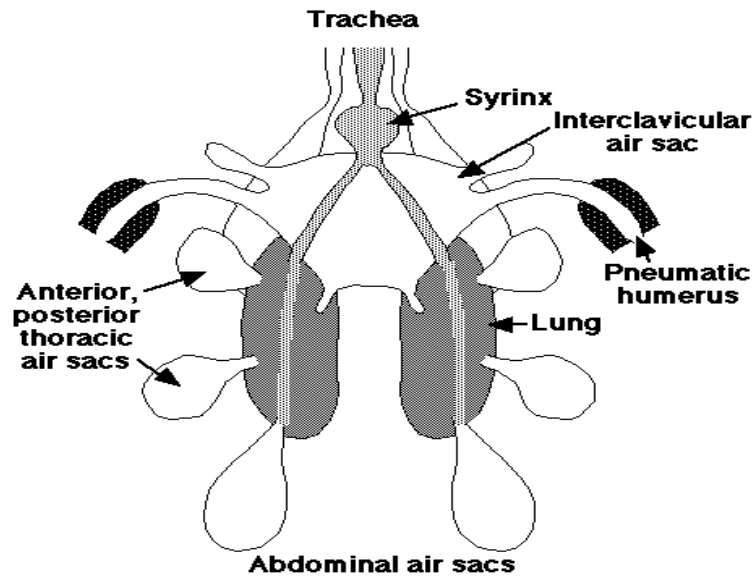


Fig.1.

Source: <http://numbat.murdoch.edu.au/Anatomy/avian/fig3.2.GIF>

2. Absence of diaphragm

Birds do not have a diaphragm; instead, air is moved in and out of the respiratory system through pressure changes in the air sacs. Birds depend on cervical, Thoracic and Abdominal muscles for inspiration and expiration both of which are active processes requiring muscular activity. Muscles in the chest cause the sternum to be pushed outward. This creates a negative pressure in the air sacs, causing air to enter the respiratory system. Expiration is not passive, but requires certain muscles to contract to increase the pressure on the air sacs and push the air out.

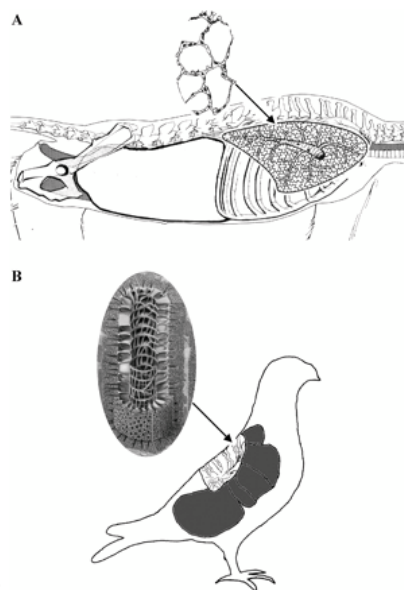


Fig.2.

The alveolar lungs of mammals (Rhesus monkey; *A*) and parabronchial lungs of birds (pigeon; *B*) are subdivided into large numbers of extremely small alveoli (*A*, inset) or air capillaries (radiating from the parabronchi; *B*, inset). The mammalian respiratory system is partitioned homogeneously, so the functions of ventilation and gas exchange are shared by alveoli and much of the lung volume. The avian respiratory system is partitioned heterogeneously, so the functions of ventilation and gas exchange are separate in the air sacs (shaded in gray) and the parabronchial lung, respectively. Air sacs act as bellows to ventilate the tube-like parabronchi (Powell and Hopkins 2004).

3. Complete tracheal rings

The tracheal cartilages in all birds form complete rings unlike C shaped incomplete rings in mammalian trachea.

Birds can breathe through the mouth or the nostrils (nares). Air entering these openings (during inspiration) passes through the pharynx & then into the trachea (or windpipe). The trachea is generally as long as the neck. However, some birds, such as cranes, have an exceptionally long (up to 1.5 m) trachea that is coiled within the hollowed keel of the breastbone.

The typical bird trachea is 2.7 times longer and 1.29 times wider than that of similarly-sized mammals. The net effect is that tracheal resistance to air flow is similar to that in mammals, but the tracheal dead space volume is about 4.5 times larger. Birds compensate for the larger tracheal dead space by having a relatively larger tidal volume and a lower respiratory frequency, approximately one-third that of mammals. These two factors lessen the impact of the larger tracheal dead space volume on ventilation. Thus, minute tracheal ventilation is only about 1.5 to 1.9 times that of mammals (Ludders 2001).

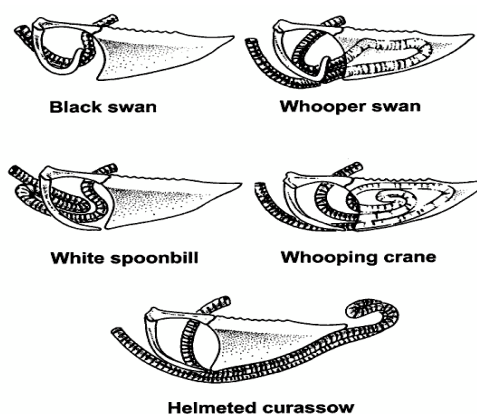


Fig.3.

Examples of tracheal loops found in Black Swans (*Cygnus atratus*), Whooper Swans (*Cygnus cygnus*), White Spoonbills (*Platalea leucorodia*), Helmeted Curassow (*Crax pauxi*), and Whooping Cranes (*Grus americana*).

Source: http://www.ivis.org/advances/Anesthesia_Gleed/ludders2/chapter_frm.asp

Interspecies variations

There are tremendous variations in tracheal anatomy that have significant implications for ventilation. (**Fig.3**)

- Emu and rudy ducks for example have an inflatable sac like diverticulum that opens from the trachea, while males of many waterfowl species have a tracheal bulbous expansion.
- Some penguins and petrels or within thorax and keel have a double trachea, and other classes of birds have complex tracheal loops or coils that may be located in the caudal neck or within the keel.

4. The trachea bifurcates (or splits) into two primary bronchi at the syrinx.

- The syrinx is unique to birds & is their 'voicebox' (in mammals, sounds are produced in the larynx).

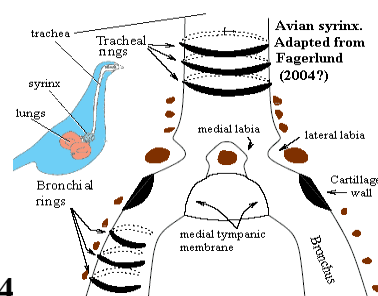


Fig.4

- The **primary bronchi** enter the lungs and they have a well developed layer of smooth muscle that consists of an inner circular layer and a longitudinally oriented layer, in response to appropriate stimuli the muscles change the internal diameter of primary bronchus.
- Branching off from the **primary bronchi** are smaller tubes called **secondary bronchi**. In most birds they are arranged into four groups : medioventral, mediodorsal, lateroventral and laterodorsal. These give rise to numerous tertiary bronchi or parabronchi in all planes.

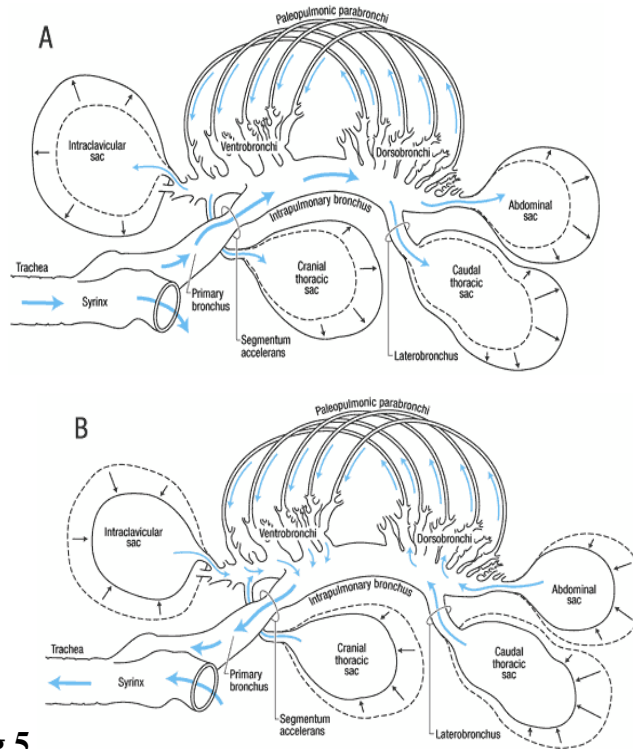


Fig.5.

Schematic representation of the right paleopulmonic lung and air sacs of a bird and the pathway of gas flow through the pulmonary system during inspiration and expiration. For purposes of clarity, the neopulmonic lung is not shown. The intrapulmonary bronchus is also known as the mesobronchus.

A - Inspiration. B - Expiration

Source: http://www.ivis.org/advances/Anesthesia_Gleed/ludders2/chapter_frm.asp

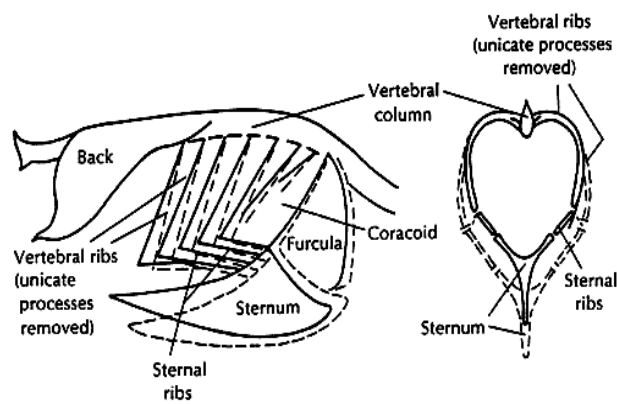


Fig.6.

Changes in the position of the thoracic skeleton occurs during breathing in a bird. The solid lines represent thoracic position at the end of expiration while the dotted lines show the thoracic position at the end of inspiration.

(Source: http://www.ivis.org/advances/Anesthesia_Gleed/ludders2/chapter_frm.asp).

- **The tertiary bronchus or Parabronchi** and its mantle of surrounding tissue comprise the basic unit for gas exchange. (Fig. They exhibit high degree of anastomosis, and their entrances are guarded by smooth muscles controlled by vagus nerves. These tubes can be several millimeters long and 0.5 - 2.0 mm in diameter (depending on the size of the bird) (Maina 1989) and their walls contain hundreds of tiny, branching, & anastomosing '**air capillaries**' surrounded by a profuse network of blood capillaries (Welty & Baptista 1988). It's within these 'air capillaries' that the exchange of gases (oxygen and carbon dioxide) between the lungs & the blood occurs.

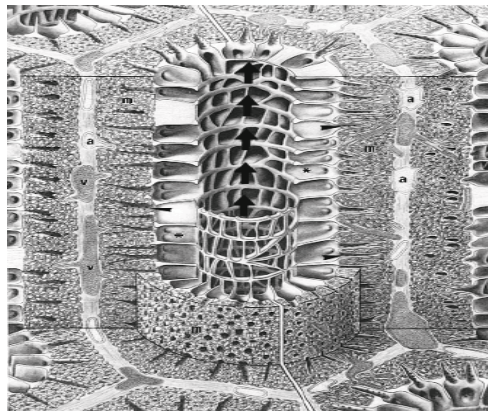


Fig.7.

Interspecies variations

The surface area for gas exchange varies from species to species, from a low value of about 10cm²/gm body wt. in domestic chicken to a high value of 87 cm²/ gm body wt. in humming bird. In bats, the only flying mammal the surface area is 63 cm².

Another factor necessary for gas exchange is the blood gas barrier and the harmonic mean thickness which is the reciprocal of mean of the thickness at every point of the barrier. The harmonic mean thickness in domestic chickens is 0.314 and humming birds is 0.099 μm (Maina and West 2005). A greater surface area and smaller mean thickness contribute to making avian lung an extremely efficient gas exchanger. Birds have particularly thinner barriers than bats and non-flying mammals (Maina 2000).

There are two types of parabronchi

- (1) The paleopulmonic tissue found in all birds and consist of parallel stacks of profusely anastomosing parabronchi.
- (2) The neopulmonic tissue located in the caudolateral portion of the lung.

Interspecies variations: (Figs.8. a, b, c)

- Penguins and emus have only paleopulmonic parabronchi.
- Pigeons, ducks and cranes have both paleopulmonic and neopulmonic parabronchi.
- In fowl like birds and song birds the neopulmonic parabronchi is more developed and account for 20-25 % of the lung volume.

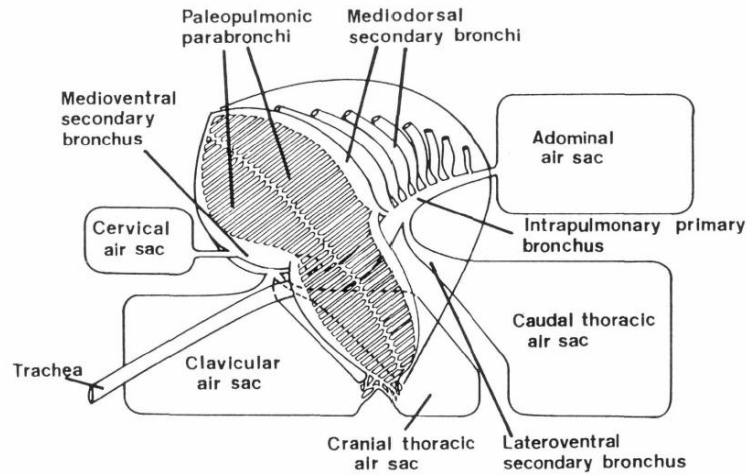


FIG. 3. Schematic drawing of the arrangement of the intrapulmonary tubular system in penguins and emus, both of which possess only paleopulmonic parabronchi. Note the parallel and orderly arrangement of the paleopulmonic parabronchi. Modified from Duncker (1972).

Fig.8.a.

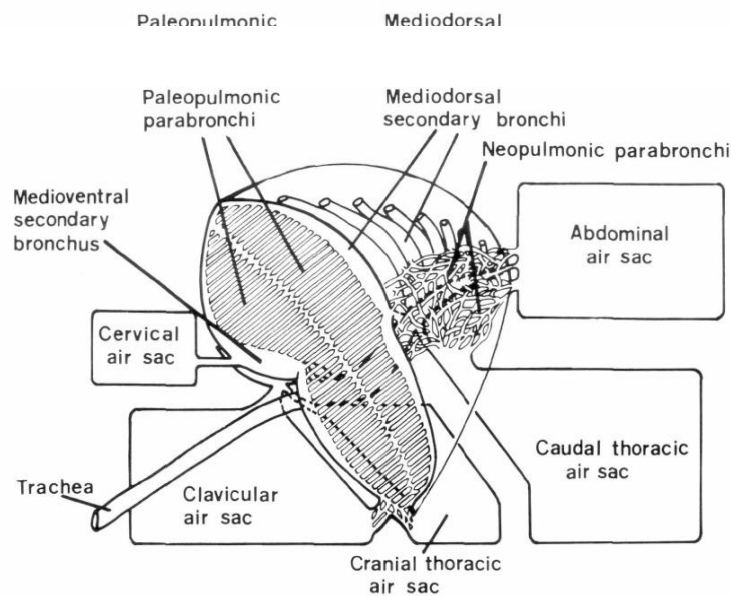


FIG. 4. Schematic drawing of the arrangement of the intrapulmonary tubular system in birds, such as storks, ducks, and geese, with paleopulmonic parabronchi and a small neopulmonic parabronchial network. The neopulmonic parabronchi vary in length and are highly interconnected but are identical to paleopulmonic parabronchi when observed histologically in cross-section. Modified from Duncker (1972).

Fig. 8.b.

Downloaded from <http://ps.oxfordjournals.org/> by guest on September 2, 2015

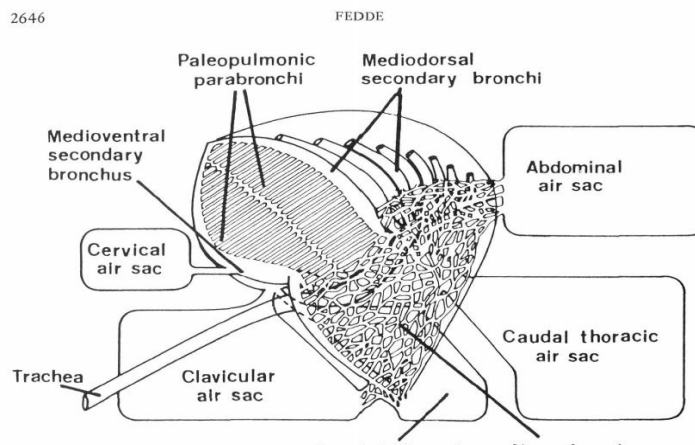


Fig.8.c.

FIG. 5. Schematic drawing of the arrangement of the intrapulmonary tubular system in birds, such as chickens, sparrows, and other song birds, with a well developed neopulmonic parabronchial network. The neopulmo covers the ventrolateral aspect of the lung to the extent that the mediodorsal secondary bronchi cannot be readily visualized on the lateral surface. Modified from Duncker (1972).

5. Presence of pneumatic bones

Diverticula from air sacs aerate the cervical vertebrae, some of the thoracic vertebrae, vertebral ribs, sternum, humerus, pelvis, head and body of femur.

6. Gas exchange

There is a cross current arrangement of gas and blood in the avian lung. The lungs receive mixed blood (high in CO₂ and low in O₂) and is uniformly distributed to all the capillaries which reunite again into venules and drawing all the missed blood (high in O₂ and low in CO₂).

All segments of a parabronchus receive mixed venous blood that traverses perpendicular to the direction of gas flow in the parabronchial lumen. This gas-to blood flow arrangement forms a cross-current exchange system, which has potentially greater efficiency than the mammalian lung arrangement allows (Piiper and Scheid, 1972).

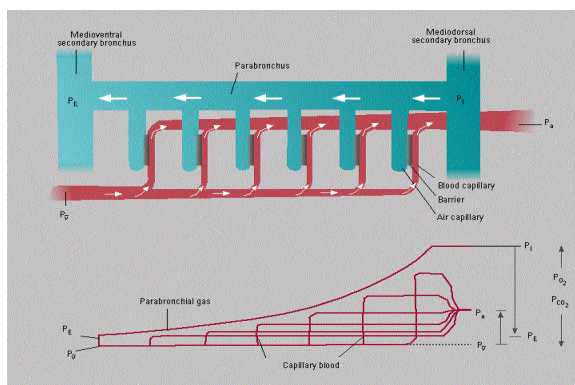


Fig. 9.

Top: Schematic of air flow (large arrows) and blood flow (small arrows) patterns constituting the cross-current gas-exchange mechanism operating in the avian lung. Note the serial arrangement of blood capillaries running from the periphery to the lumen of the parabronchus and the air capillaries radially departing from the parabronchial lumen. **Bottom:** Pressure profiles of O₂ and CO₂ from initial-parabronchial (PI) to end-parabronchial values (PE); and in blood capillaries from mixed venous (P_v) to arterial blood (P_a). The PO₂ of arterial blood is derived from a mixture of all serial air-blood capillary units and exceeds that of PE. In mammals, the PaO₂ cannot exceed that of end- expiratory gas (i.e., PE) (Brown *et al.*, 1997).

The few hundred to thousand parabronchi, one of which is fully shown here, are packed tightly into a hexagonal array. The central parabronchial lumen, through which gas flows unidirectionally during both inspiration and expiration (large arrows) is surrounded by a mantle (m) of gas-exchange tissue composed of an intertwined network of blood and air capillaries. Several air capillaries coalesce into a small manifold, i.e., the infundibulum (arrowheads), several of which in turn open into atria (*) found along the parabronchial lumen. Air moves convectively through the parabronchial lumen, while O₂ diffuses radially (CO₂ diffuses centrally) into the air capillary network. Blood flows centrally from the pulmonary arteries (a) located along the periphery of the parabronchi to pulmonary veins located along the parabronchial lumen, which then are drained back to the peripheral veins (v) (Modified from Duncker, 1971).

Table 1. Gas exchange variables in awake resting birds

Variable*	Common starling	Pigeon	Black duck	Domestic fowl	Muscovy duck	Pekin duck
Weight (kg)	0,08	0.38	1.03	1.6	2.16	2.38
MO ₂ (mmol/min)	013	0.35	0.84	1.09	-----	1.67
F (resp./min)	920.67	27	27	23	10	8-15
V _T (ml)	0.061	7.5	30	33	69	16-98
V _E (L/min)	-----	0.204	0.79	0.760	0.70	0.807-0.910
Q (L/min)	-----	0.127	-----	0.430	0.84	0.42-0.97
Pa O ₂ (mmHg)	-----	95	-----	87	96	93-100
PaCO ₂ (mmHg)	-----	34	-----	29	36	34-36

Adapted from Powell and Sheid 1989, in King and McLelland, eds., Form and Function in birds, vol. 4., Academic Press, New York.

*MO₂ (mmol/min)-oxygen consumption, F (resp./min)-respiratory frequency, V_T (ml)- tidal volume, V_E (L/min)-minute ventilation (L/min)-cardiac output, Pa O₂ (mmHg)- partial pressure of oxygen, Pa CO₂ (mmHg)- partial pressure of carbon dioxide.

Avian haemoglobin

There are some characteristic features in avian hemoglobin. On adult birds there are two different types of hemoglobin; A & D. The A form is more prevalent form which has a lower affinity for hemoglobin, and therefore more readily dissociates from hemoglobin.

Co-operativity

The tendency by which a bound O₂ facilitates the binding of another molecule is called cooperativity. Another term defining cooperativity is the Hill co-efficient, which is directly proportional to it. This is high in case of hemoglobin A.

Another feature of avian hemoglobin is its interaction with inositol pentaphosphate and inositol tetraphosphate, which shifts the O₂-Hb dissociation curve to right and decreases the affinity of oxygen for hemoglobin, enhancing the delivery of oxygen to tissues.

Surfactant SP-B (in the figure above) is mixture of phospholipids and specific proteins that functions to maintain airflow through the 'tubes' of the avian respiratory system. Surfactant SP-A has only been detected in the mesobronchi of birds. SP-A plays an important role in innate host defense and regulation of inflammatory processes and may be important in the mesobronchi because air flow is slower and small particles could tend to accumulate there (see figure below). Surfactant SP-C is not found in the avian respiratory system (or, if so, in very small quantities), but is found in the alveoli of mammals along with SP-A and SP-B. Because the mammalian respiratory system (below) includes structures that are collapsible (alveoli) and areas with low airflow, all three surfactants are important for reducing surface tension and innate host defense (Bernhard *et al.*, 2004).

Control of ventilation

As in mammals the central pattern generator is located in the pons and medulla with facilitation and inhibition from higher centres in the brain. It is also influenced by the feedback from chemo, mechano and thermo receptors (Ludders, 2001).

- The peripheral extrapulmonary chemoreceptors are located in the carotid bodies influenced by PaO₂ changes. But unlike in mammals a unique group of chemoreceptors called intrapulmonary chemoreceptors (IPCs) are located in lungs and are acutely sensitive to carbon dioxide and insensitive to hypoxia.
- The mechanoreceptors are located in the walls of air sacs and in surrounding tissues and are sensitive to inflation of respiratory system.

- Thermoreceptors are located centrally and peripherally and their signals are integrated in the hypothalamus.
- The receptivity and activity of peripheral receptors varies tremendously from flight birds to non-flight birds.

SUMMARY

Further research is demanded on the interspecies variations regarding the control of ventilation, the development of different parabronchi in different avian species and the extent of nervous innervations in the parabronchial mass.

REFERENCES

1. Brown, R.E., J. D. Brain, and N. Wang. The Avian Respiratory System: A Unique Model for Studies of Respiratory Toxicosis and for Monitoring Air Quality. *Environ Health Perspectives*, 1997; 105: 188-200.
2. Bernhard, W., P. L. Haslam, and J. Floros. From birds to humans: new concepts on airways relative to alveolar surfactant. *American Journal of Respiratory Cell and Molecular Biology*, 2004; 30: 6-11.
3. Duncker, H.-R. The lung air sac system of birds. *Advances in Anatomy, Embryology, and Cell Biology*, 1971; 45: 1-171.
4. Duncker, H.-R. Structure of avian lungs. *Respir. Physiol*, 1972; 14: 44-63.
5. Ludders, J.W. 2001. Inhaled Anesthesia for Birds. In: *Recent Advances in Veterinary Anesthesia and Analgesia: Companion Animals* (R. D. Gleed and J. W. Ludders, eds.). International Veterinary Information Service, Ithaca, NY.
6. Maina, J. N. Comparative respiratory morphology: Themes and principles in the design and construction of the gas exchangers. *Anatomical Record*, 2000; 261: 25-44.
7. Maina, J. N. and C. Nathaniel. A qualitative and quantitative study of the lung of an ostrich, *Struthio camelus*. *Journal of Experimental Biology*, 2001; 204: 2313-2330.
8. Maina, J. N. and John B. West. Thin and strong! The bioengineering dilemma in the structural and functional design of the blood- gas barrier. *Physiol.Rev*, 2005; 85: 811-844.
9. Maina, J.N. 1989. The morphometry of the avian lung. Pp. 307-368 in *Form and Function in Birds* (A.S. King and J. McLelland, eds.). Academic Press, London.
10. Nganpiep, L. N. and J. N. Maina. Composite cellular defence stratagem in the avian respiratory system: functional morphology of the free (surface) macrophages and specialized pulmonary epithelia. *Journal of Anatomy*, 2002; 200: 499-516.

11. Piiper, J., and P. Scheid. Maximum gas transfer efficacy of models for fish gills, avian lungs and mammalian lungs. *Respir. Physiol*, 1972; 14: 115-124.
12. Powell, F. L. and S. R. Hopkins. Comparative physiology of lung complexity: implications for gas exchange. *News in Physiological Science*, 2004; 19: 55-60.
13. Welty, J.C. and L. Baptista. 1988. *The life of birds*, fourth edition. Saunders College Publishing, New York, NY.