



## CBCT AIDED ENDODONTIC MANAGEMENT OF MAXILLARY FIRST MOLAR WITH 5 CANALS: A CASE REPORT

**Dr. Harshita<sup>1\*</sup>, Prashant Monga<sup>2</sup>, Pardeep Mahajan<sup>3</sup>, Pratima Sharma<sup>4</sup>, Harsimranjit Kaur<sup>5</sup>, Palvi Dhand Gupta<sup>6</sup>, Sakshi Garg<sup>7</sup> and Amitoj Kaur Walia<sup>8</sup>**

<sup>1,4,5,6</sup>Post Graduate Student, Department of Conservative Dentistry and Endodontics, Genesis Institute of Dental Sciences and Research, Ferozepur, Punjab.

<sup>2</sup>MDS, Reader, Department of Conservative Dentistry and Endodontics, Genesis Institute of Dental Sciences and Research, Ferozepur, Punjab.

<sup>3</sup>MDS, Prof. and HOD, Department of Conservative Dentistry and Endodontics, Genesis Institute of Dental Sciences and Research, Ferozepur, Punjab.

<sup>7</sup>Post Graduate Student, Department of Prosthodontics including Crown and Bridge, Surendra Dental College and Research Institute, Sri Ganganagar, Rajasthan, India.

<sup>8</sup>Tutor, Department of Conservative Dentistry and Endodontics, Genesis Institute of Dental Sciences and Research, Ferozepur, Punjab.

**\*Corresponding Author: Dr. Harshita**

Post Graduate Student, Department of Conservative Dentistry and Endodontics, Genesis Institute of Dental Sciences and Research, Ferozepur, Punjab.

Article Received on 12/06/2018

Article Revised on 02/07/2018

Article Accepted on 23/07/2018

### ABSTRACT

Root canal treatment is a technically demanding procedure especially in the case of maxillary first molar where the anatomy is extremely variable. Presence of extra canals is a common finding. Failure to recognise and treat these variations may lead to unpredictable outcomes. This case report presents the endodontic management of a maxillary first molar with three roots and five canals. A 40-year-old man came with history of discomfort on chewing in the right upper tooth region for 1 week. Periapical radiograph revealed mesio-occlusal caries with pulp involvement and the mesial root was associated with localised well-circumscribed radiolucency. De-roofing of the pulp chamber were done to provide straight line access to the canals. CBCT scan was performed with a tube voltage of 100 KV and a tube current of 8 mA. CBCT scan slices revealed five canals (two mesiobuccal, two distobuccal and one palatal) in the right maxillary first molar. The clinical detection of the five canals was made using a surgical operating microscope and confirmed using cone-beam computed tomography (CBCT) scanning. It also highlights the need for thorough knowledge of root canal morphology and its variations in order to achieve consistently successful results.

**KEYWORDS:** Maxillary first molar; Cone beam computerized tomography scanning; Surgical microscope; Root canal anatomy.

### INTRODUCTION

The morphology of the permanent maxillary first molar has been studied by various authors.<sup>[1]</sup> The root canal anatomy of maxillary first molar has been traditionally described as three roots with three canals, and the commonest variation is the presence of a second mesiobuccal canal (MB2). Special attention is always paid to the second mesio-buccal canal (MB2 and DB2), which, according to many authors, commonly presents variation.

The incidence of second mesiobuccal canal has been reported to be between 18% and 96.1%. The incidence of two canals in the distobuccal root as 1.90% and 4.30%, respectively as reported by Alavi et al and Thomas et

al.<sup>[1]</sup> So, the incidence of fifth canal i.e. DB2 is very rare as compared to MB2.

Acosta Vigouroux and Trugeda Bosaans reported 5 root canals in only 2.25% of maxillary first molars. Gray reported 5 canals in 2.4% of the teeth, with the following distribution: MB1 and MB2, DB1 and DB2, and one palatal canal.<sup>[2]</sup>

The increasing reports of more than one mesiobuccal canal and additional distobuccal canals in the recent years can be attributed to the increased knowledge of the root canal complex morphology, advanced diagnostic tools such as cone-beam computed tomography (CBCT) and micro-computed tomography and using equipment

such as dental operating microscope, ultrasonics, and specialized instruments.<sup>[5]</sup>

The present case report discusses the successful endodontic management of a maxillary first molar presenting with three roots and five root canals. This unusual morphology was confirmed with the help of CBCT scans.

## MATERIAL AND METHODS

A 40-year-old man came to the Department of Conservative Dentistry and Endodontics, Genesis Institute Of Dental Sciences and Research Ferozepur, with history of discomfort on chewing in the right upper tooth region for 1 week. The patient did not give any history of spontaneous or nocturnal pain and there was no history of any swelling or fever associated with the pain. The patient's medical history was noncontributory.

Intraoral examination revealed mesio-occlusal caries in tooth #16 with pulp involvement. This tooth was slightly tender on percussion and did not show any response on thermal testing. Periapical radiograph (Fig. no. 1) revealed mesio-occlusal caries with pulp involvement and the mesial root was associated with localised well-circumscribed radiolucency as confirmed by radiograph. Therefore, according to AAE Recommended Diagnostic Terminology, a diagnosis of pulpal necrosis associated with chronic periapical periodontitis was made. So, the treatment plan was made to perform the root canal treatment of the particular tooth.

After a thorough discussion about the treatment and its outcome, root canal treatment was initiated with patient's consent. The patient was locally anesthised with 2% lidocaine with 1:100,000 epinephrine. A rubber dam was placed, and a conventional endodontic access opening was made.

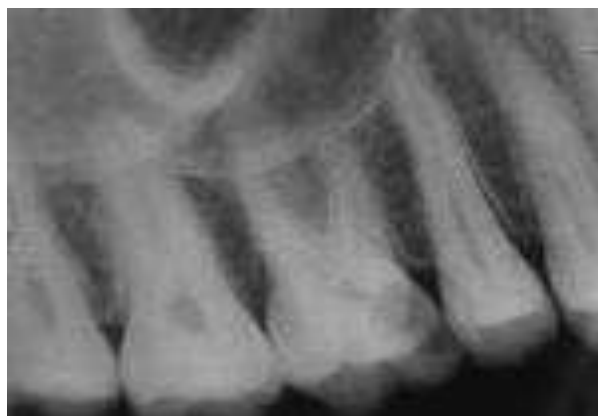Extension and de-roofing of the pulp chamber were done to provide straight line access to the canals. Coronal pulp was removed. The three principal canals namely mesiobuccal, distobuccal, and palatal canals were identified. After probing with a Hu-Friedy DG 16 endodontic explorer, it revealed two canal openings in each of the distobuccal, mesiobuccal root canal. The conventional triangular access was modified to a trapezoidal shape to improve the access. Five canals were located in the floor of the pulp chamber, namely two mesiobuccal, two distobuccal and one palatal (Fig no. 2).

The working length was determined with the help of an apex apex locator (Root ZX, J.Morita Inc. USA) and later confirmed by an IOPA radiograph (Fig no. 3). Multiple working length radiographs were taken at different angulations. However, the radiographs did not clearly reveal the number and morphology of root canal systems.

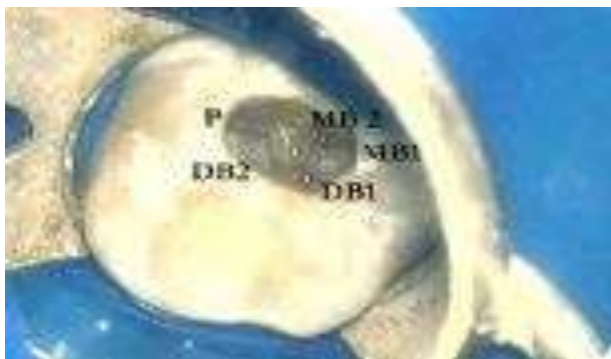To confirm this unusual morphology, it was decided to perform CBCT imaging of the tooth. Access cavity was sealed with IRM cement (Dentsply De Trey GmbH, Konstanz, Germany). An informed consent was obtained from the patient, and a multislice CBCT scan was performed (Simulix Evolution; Nucletron, Chennai, India Pvt Ltd) with a tube voltage of 100 KV and a tube current of 8 mA. The involved tooth was focused, and the morphology was obtained in coronal middle and apical, sections of 0.5-mm thickness. CBCT scan slices revealed five canals (two mesiobuccal, two distobuccal and one palatal) in the right maxillary first molar (Fig No. 4).

At the second appointment, the patient was asymptomatic. Cleaning and shaping was performed under rubber dam isolation using Pro-Taper nickel-titanium rotary instruments (Dentsply Maillefer) with a crown-down technique as recommended by manufacturer.

Irrigation was done using normal 5 ml of 3% NaOCl (Shiva Products, Waliv, Palghar, Maharashtra, India) as an irrigant followed by 5 ml of normal saline solution after each instrumentation. Final irrigation was done with 2% chlorhexidine for final flush. The canals were dried with absorbent points (Dentsply Maillefer) and calcium hydroxide closed dressing was given and tooth was sealed with IRM cement (Dentsply Maillefer). One week later, at the third appointment, all canals were irrigated using sterile normal saline followed by 10ml of 17% liquid EDTA and dried with absorbent paper points (Dentsply Maillefer), and obturation was performed using gutta-percha (Dentsply Maillefer) and AH Plus resin sealer (Maillefer, Dentsply, Konstanz, Germany) (Fig.5). The obturated tooth was then restored with a posterior composite resin (P60; 3M Dental Products, St Paul, MN). The patient was advised a full-veneer crown. Follow-up evaluation at 6 months and 1-year was done which showed satisfactory results.



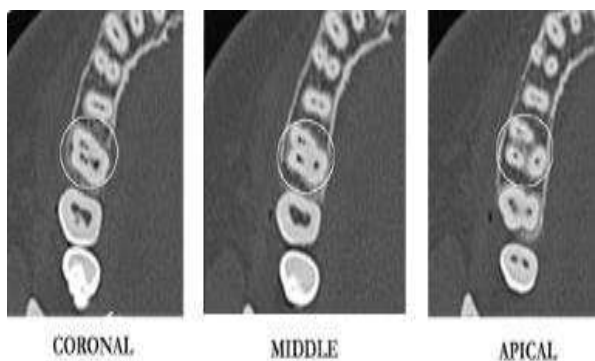
**Fig. No. 1: Preoperative IOPA showing caries with pulp involvement in relation to 16.**



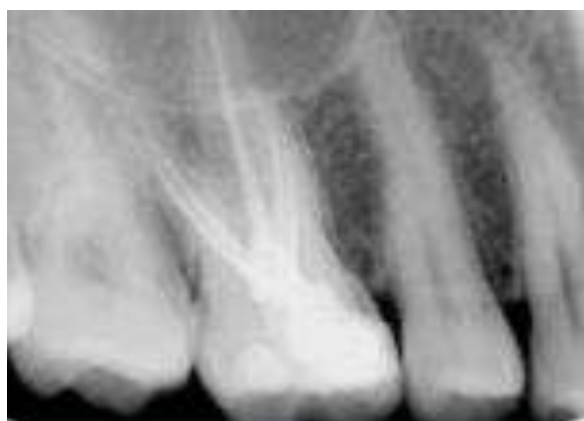**Fig. No. 2: Access opening showing 5 orifices in relation to 16.**



**Fig. No. 3: Working length determination in relation to 16.**



**Fig. No. 4: CBCT scans saggital sections showing five canals.**



**Fig. 5: Obturation done in relation to 16.**

## DISCUSSION

Although, radiographic examination is an essential component of the management of endodontic problems. But the amount of information gained from conventional radiographs and digitally captured periapical radiographs is limited by the fact that the three-dimensional anatomy of the area being radiographed is compressed into a two-dimensional image.<sup>[1]</sup>

An inability to locate MB2 and DB2 root canal of maxillary molars may be a major cause of the failure of root canal treatment. According to studies done by James Wolcott et al, 35% of maxillary 2nd molars had MB2 canal compared to 60% that of maxillary 1st molars.<sup>[4]</sup> The openings of MB2 and DB2 canals are localized on an imaginary line between the MB1 and palatal orifice and DB1 and palatal orifice, respectively.<sup>[5]</sup>

The methods to explore additional canal orifices have always been an important area of discussion and various tools have been used for this purpose. They are:<sup>[6]</sup>

- Magnifying loupes and surgical operating microscope
- Examination of the pulp chamber floor with a sharp explorer, performing the sodium hypochlorite “champagne bubble test,” and visualizing canal bleeding points are the commonly followed methods for detection of canal orifices.

Dental Operating Microscopes (DOM) improve the light and magnification in the operating field, thereby increasing the ability to locate missed a canal and decreasing the risk of procedural errors. Consequently, DOM is be considered as an important aid in contemporary endodontic practice.<sup>[7]</sup>

This case report emphasizes the importance of the use of magnification for exploring the canals and modification of access cavity to ensure the proper endodontic treatment. Weller and Hartwell showed that modification of the access cavity from a conventional triangular to rhomboidal shape, exploration of the groove running from the MB to palatal and removal of any projections that may conceal the canal orifice enhances the chances of locating the additional canals.<sup>[8]</sup>

In recent years, CBCT has been proven to be useful for studying root canal morphology, complicated root canal treatment cases.<sup>[9]</sup> In this study, the CBCT was done to take advantages of good resolution and three-dimensional presentation. In spite of the superiority of CBCT, CBCT is still not recommended instead of traditional X-ray films during initial steps in endodontic application under consideration of the ALARA principle.<sup>[9]</sup>

The present case highlights the importance of CBCT scanning for a better understanding of the complex root canal anatomy. CBCT confirmed the unusual anatomy of a maxillary first molar with five canals 2 mesiobuccal

canals i.e. MB1, MB2 and 2 distobuccal canals i.e. DB1 and DB2 and 1 palatal canal. CBCT images also showed that both mesial and distal canals presented with a Vertucci type III canal pattern (i.e., two canal orifices with two separate exists).<sup>[10]</sup>

Clinical studies have always shown a higher prevalence of the second canal in the mesiobuccal and distobuccal roots.<sup>[8]</sup> Thus, CBCT scanning was pivotal in the diagnosis of this unusual root canal anatomy and towards its successful endodontic management.

## CONCLUSION

This case report contributes to our understanding of root canal morphology found in a maxillary first molar and also highlights the role of surgical operating microscope and CBCT scanning as an objective analytic tool to ascertain root canal morphology. Hence, dentists performing endodontic treatment in maxillary first molars should always look for extra number of canals and complex canal systems to achieve predictable success.

## REFERENCES

1. Kulild JC, Peters DD. Incidence and configuration of canal systems in the mesiobuccal root of maxillary first and second molars. *J Endod* 1990; 16(3): 11-7.
2. Acosta Vigouroux SA, Trugeda Bosaans SA. Anatomy of the pulp chamber floor of the permanent maxillary first molars. *J Endod*, 1978; 4(7): 214-9.
3. Anand P, Mahalaxmi S. Maxillary first molar with 5 canals. *SRM J Res Dent Sci.*, 2016; 7: 45-7.
4. Mehta P, Raisingani D, Mathur R, Jindal D. Endodontic management of maxillary second molar having unusual anatomy with three mesiobuccal root canals: A Case report, *International Journal of Oral Health Sciences*, 2013; 3(2): 113-6.
5. Mitthra S, Kittapa K, Sekar M. Maxillary second molar with fused root and six canals: A Case report, *Journal of Clinical and Diagnostic Research*, 2017; 11(4): 35-7.
6. Bhamidi A, Bashetty K, Karale R. Maxillary first molar with six canals: A case report. *Int J Med Dent Case Rep*, 2014; 4(7): 1-3.
7. Stropko JJ. Canal morphology of maxillary molars: clinical observations of canal configurations. *J Endod*, 1999; 25: 446-50.
8. Weller RN, Hartwell GR. The impact of improved access and searching techniques on detection of the mesiolingual canal in maxillary molars. *J Endod*, 1989; 15: 82-3.
9. Tsiklakis K, Donta C, Gavala S, Karayianni K, Kamenopoulou V, and Hourdakos CJ. Dose reduction in maxillofacial imaging using low dose Cone Beam CT, *European Journal of Radiology*, 2005; 56(3): 413-7.
10. Fava L R G. Root canal treatment in an unusual maxillary first molar: a case report. *Int Endod J.*, 2001; 34: 649-53.