

COMPARISON BETWEEN DIFFERENT DIAGNOSTIC METHODS TO DETERMINE THE HOSPITAL PREVALENCE OF THEILERIA ANNULATA INFECTION IN CATTLE-CALVES IN BIKANER

*¹Pavan Goyal, ¹Anju Chahar, ²S. S. Soni and ²B. N. Shringi

¹Department of Epidemiology and Preventive Veterinary Medicine, College of Veterinary and Animal Science, RAJUVAS, Bikaner, Rajasthan, India.

²Department of Veterinary Microbiology and Biotechnology, College of Veterinary and Animal Science, RAJUVAS, Bikaner, Rajasthan, India.

*Corresponding Author: Pavan Goyal

Department of Epidemiology and Preventive Veterinary Medicine, College of Veterinary and Animal Science, RAJUVAS, Bikaner, Rajasthan, India.

Article Received on 28/12/2017

Article Revised on 18/01/2018

Article Accepted on 08/02/2018

ABSTRACT

A total of 100 cattle-calves irrespective of their age, sex and breed brought to Teaching Veterinary Clinical Complex of College of Veterinary and Animal science, Bikaner for treatment were screened for *Theileria annulata* infection. Blood samples were collected from jugular vein aseptically in ethylene diamine tetra acetic acid (EDTA @ 1 mg/ml) vacutainer for genomic DNA isolation and isolated DNA samples were subjected to nested polymerase chain reaction (nPCR) using primer sets. Blood smears were prepared from ear vein for detection of *Theileria* piroplasms and lymph node aspirate smears were prepared from the enlarged superficial lymph nodes for detection of schizont stage in mononuclear cells under oil immersion lens. Out of 100 samples, only 7 were positive for intra-erythrocytic piroplasms, 3 for schizont stage in mononuclear cells upon microscopic examination while 41 samples were found positive for *Theileria annulata* infection by nPCR which produced 372 bp amplicon on 1% agarose gel. Thus, the hospital prevalence of *Theileria annulata* infection by Giemsa stained blood smear examination, lymph node aspirate smear examination and nPCR was 7%, 3% and 41%, respectively. Hence, nPCR showed significantly higher efficacy in detection of *Theileria annulata* infection as compared to microscopic examination.

KEYWORDS: Cattle-calves, *Theileria annulata*, piroplasms, Schizont, nPCR, agarose gel.

INTRODUCTION

Bovine tropical theileriosis is a protozoan disease caused by blood protozoa *Theileria annulata* and it is transmitted by tick *Hyalomma anatolicum anatolicum*. It causes significant economic losses in large parts of Asia.^[11] It is mainly seen in cattle, sheep and goat as well as in wild and captive ungulates.^[12] This intracellular infection inflicts economic burden on cattle breeders in terms of mortality and morbidity as well as expenses spent on prophylactic measures against disease and treatment.^[9] *Theileria* spp. infection can cause acute, subacute or chronic disease pathology.^[10] In *T. annulata* infection, the most common clinical symptoms are weakness, weight loss, anorexia, high body temperature, petechia on the conjunctival mucosa, swollen lymph nodes, anaemia and cough. On later stages of theileriosis, infected animals cannot stand up, their body temperatures are under normal values (< 38.5°C), icterus, dehydration and blood in faeces are the occasional clinical symptoms.^[3,12] Calves (≤ 4 months of age) infected with *Theileria annulata* suffered from

emaciation, anaemia, unilateral or bilateral exophthalmia, petechiae in conjunctiva, oral and nasal mucosa, and occasionally in the pinnae. Widespread subcutaneous nodules with 0.5 to 3.0 cm diameter are also detected, as well as enlarged superficial lymph nodes, particularly the submandibular, the retropharyngeal and sometimes the prescapular.^[5]

Conventional diagnosis of tropical theileriosis depends on examination of Giemsa stained thin blood and lymph node aspirate smears. This method is limited to the acute stage of the disease where the parasitemia is high enough to be detected microscopically. During chronic and carrier stages the level of parasitemia usually below the microscopical detectable level. The application of genotypic assay for the diagnosis of bovine theileriosis has shown recent advances. Molecular identification provides two primary advantages to phenotypic identification; it is more rapid turnaround time, and improved accuracy of identification.^[11] Advances in molecular diagnostic techniques have resulted in the

improved detection, identification and genetic characterization of many haemoparasites. Species-specific polymerase chain reaction (PCR) has been developed for the detection and identification of various *Theileria* species and has been shown to have higher sensitivity and specificity compared with serological assays and examination of Giemsa stained blood smears.^[4, 14] Thus PCR is thought to be more practical and widely implemented technique not only for diagnosis but also for epidemiological investigation of haemoprotozoa of dairy animals primarily in developing countries.

MATERIALS AND METHODS

A total of 100 cattle-calves irrespective of their age, sex and breed brought to Teaching Veterinary Clinical Complex of College of Veterinary and Animal science, Bikaner for treatment were screened for *Theileria annulata* infection. Blood samples were collected from jugular vein aseptically in ethylene diamine tetra acetic acid (EDTA @ 1 mg/ml) vacutainer for genomic DNA isolation. The isolated DNA samples were subjected to nested polymerase chain reaction (nPCR) using primers sets reported by^[6] and nPCR products were checked by electrophoresis on 1% agarose gel and visualized using a gel documentation system (Syngene, UK). Blood smears

were prepared from ear vein for detection of *Theileria* piroplasms and lymph node aspirate smears were prepared from the enlarged superficial lymph nodes for detection of schizont stage under oil immersion lens after staining with Giemsa stain.

RESULTS

In the present study out of 100 samples examined, only seven (7 per cent) were positive for intra-erythrocytic piroplasms and three (3 per cent) for schizont forms in mononuclear cells upon microscopic examination, whereas 41 (41 per cent) were positive for the presence of *Theileria annulata* by nPCR which produced 372 bp amplicon on 1% agarose gel. All of the samples positive by microscopic examination were also positive by nPCR. Thus, the hospital prevalence of *Theileria annulata* infection in cattle-calves by blood smear examination, lymph node aspirate smear examination and nPCR was 7%, 3% and 41%, respectively. Similar findings have also been reported by.^[7,2,8,14,13]

Comparison of different diagnostic methods such as nPCR, blood smear examination and lymph node aspirate smear examination under oil immersion is shown in Table 1 and Figure 1.

Table 1: Comparison of different diagnostic methods in regarding to hospital prevalence of *Theileria annulata*.

Diagnostic Methods	Prevalence (%)
nPCR	41
Blood smear examination	7
Lymph node aspirate smear examination	3

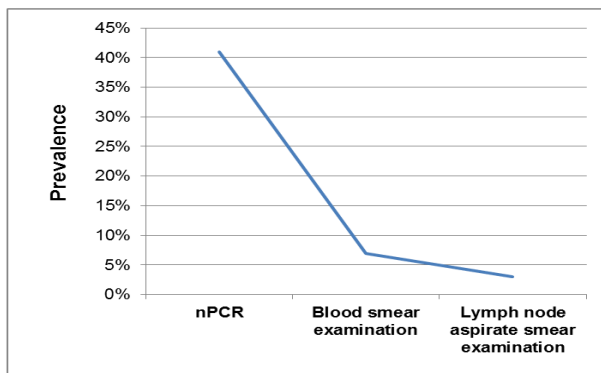


Figure 1: Line diagram showing comparison of different diagnostic methods in regarding to hospital prevalence of *T. annulata*.

DISCUSSION

When compared to microscopic examination results, nPCR showed significantly higher efficacy of detection of *Theileria* spp. In the present study, low positivity was found by conventional diagnostic method like examination of Giemsa stained blood smear and lymph node aspirate smear than nPCR. It may be due to high number of chronic cases. In these cases the level of

parasitemia was very low so, these cases were not detected by microscopic examination.

Conventional diagnosis of tropical theileriosis depends on examination of Giemsa stained thin blood and lymph node aspirate smears. This method is limited to the acute stage of the disease where the parasitemia is high enough to be detected microscopically. During chronic and carrier stages the level of parasitemia usually below the microscopical detectable level. The application of genotypic assay for the diagnosis of bovine theileriosis has shown recent advances. Molecular identification provides two primary advantages to phenotypic identification; it is more rapid turnaround time, and improved accuracy of identification.^[1]

CONCLUSIONS

Conclusively, nPCR in this study is found to be more accurate not only for diagnosis but also for epidemiological investigation of haemoprotozoa-*Theileria annulata* infection in cattle-calves in Rajasthan.

ACKNOWLEDGEMENT

The authors are highly thankful to the Dean and Dr. G.C. Gahlot, Professor and Head, Department of Animal

Genetics and Breeding, College of Veterinary and Animal Science, Bikaner, Rajasthan for providing necessary facilities to carry out the present investigation. This study is financially supported by the Rajasthan University of Veterinary and Animal Sciences, Bikaner, Rajasthan.

REFERENCES

1. Aktas M, Altay K, Dumanli N Prevalence and distribution of tropical theileriosis in eastern Turkey. *Vet. Parasitol*, 2005; 127: 9–15.
2. Aktas M, Altay K, Dumanli N A molecular survey of bovine *Theileria* parasites among apparently healthy cattle and with a note on the distribution of ticks in eastern Turkey. *Vet. Parasitol*, 2006; 138: 179–185.
3. Bakheit MA, Schnittger J, Salih, DA, Boguslawski K, Beyer D, Fadl M, Ahmed JS Application of the recombinant *Theileria annulata* surface protein in an indirect ELISA for the diagnosis of tropical theileriosis. *Parasitol Res*, 2004; 92: 299–302.
4. Bhoora R, Franssen L, Oosthuizen MC, Guthrie AJ, Zwegarth E, Penzhorn BL, Jongejan F, Collins NE Sequence heterogeneity in the 18S rRNA gene within *Theileria equi* and *Babesia caballi* from horses in South Africa. *Veterinary Parasitology*, 2009; 159: 112–120.
5. Branco S, Orvalho J, Leitao A, Pereira I, Malta M, Mariano I., Carvalho T, Baptista R, Shiels BR, Peleteiro MC (2010). Fatal cases of *Theileria annulata* infection in calves in Portugal associated with neoplastic-like lymphoid cell proliferation. *J. Vet. Sci*, 2010; 11(1): 27–34.
6. D'Oliveira C, Vandermerve M, Habela M, Jacquiet P, Jongejan F Detection of *Theileria annulata* in blood samples of carrier cattle by PCR. *J. Clin. Microbiol*, 1995; 33(10): 2665–2669.
7. Dumanli N, Aktas M, Cetinkaya B, Cakmak A, Koroglu E, Saki CE, Erdogmus Z, Nalbantoglu S, Ongor H, Simsek S, Karahan M, Altay K Prevalence and distribution of tropical theileriosis in eastern Turkey. *Veterinary Parasitol*, 2005; 127: 9–15.
8. Durrani AZ, Mahmood N, Shakoori AR Comparison of three diagnostic methods for *Theileria annulata* in Sahiwal and Friesian cattle in Pakistan. *Pak. J. Zool*, 2010; 42(4): 467–472.
9. Durrani AZ, Shakoori AR, Kamal N Bionomics of *Hyalomma* ticks in three districts of Punjab. *Pakistan J. Anim. Plant Sci*, 2008; 18(1): 20–23.
10. Gill BS, Bhattacharyulu Y, Kaur D Symptoms and pathology of experimental bovine tropical theileriosis (*Theileria annulata* infection). *Annales de Parasitologie Humaine et Comparee*, 1977; 52: 597–608.
11. Hasanpour A, Sabegh YG, Sadeghi-nasab A Assessment of serum antioxidant enzymes activity in cattle suffering from theileriosis. *European Journal of Experimental Biology*, 2013; 3(1): 93–96.
12. Radostits OM, Gay CC, Hinchcliff KW, Constable PD. *Veterinary Medicine*. 10th ed., Philadelphia; W.B. Saunders Company Ltd., 2007.
13. Saeid RNF, Khalili M, Ghalekhani N Detection of *Theileria annulata* in blood samples of native cattle by PCR and smear method in Southeast of Iran. *J. Parasit Dis*, 2013; DOI 10.1007/s12639-013-0333-2.
14. Shahnawaz S, Ali M, Aslam MA, Fatima R, Chaudhary ZI, Hassan MU, Ali M, Iqbal F A study on the prevalence of a tick transmitted pathogen, *Theileria annulata*, the haematological profile of cattle from Southern Punjab (Pakistan). *Parasitol. Res*, 2011; 109: 1155–1160.