



DESMOID FIBROMATOSIS OF THE BREAST

Elmoudane Jihane*, Oubel Naoual, Halim Hajare, Slaoui Aziz, Lakhdar Amina and Baydada Aziz

Department of Gynecology-Obstetrics Souissi Maternity Hospital - CHU Ibn Sina Rabat- Morocco.



*Corresponding Author: Elmoudane Jihane

Department of Gynecology-Obstetrics Souissi Maternity Hospital - CHU Ibn Sina Rabat- Morocco.

Article Received on 27/12/2023

Article Revised on 16/01/2024

Article Accepted on 06/02/2024

ABSTRACT

Desmoid fibromatosis of the breast is a rare benign condition of the breast (0.2% of breast tumors) that clinically and sonographically mimics breast cancer. The diagnosis is confirmed by histology, allowing the elimination of the main differential diagnosis of this entity which is metaplastic spindle cell carcinoma. Breast fibromatosis is characterized by a local evolution and a tendency to recurrence, hence the interest of surgical excision with healthy margins. Radiation therapy should be discussed in such cases. Through our case and the review of the literature, we will try to focus on the diagnosis of this rare entity and its management because it influences the prognosis. In conclusion, breast fibromatosis must be known since it mimics breast cancer in every way and is characterized by a very high rate of recurrence without ever causing metastases.

KEYWORDS: Fibromatosis; Breast; Diagnosis; Risk; Surveillance.

1- INTRODUCTION

Breast fibromatosis is a benign, mesenchymal tumor that develops from musculo-aponeurotic structures. It is a rare tumor entity and represents 0.2% of primary breast tumors and 4% of extra-abdominal fibromatoses.^[1] This pathology mimics breast cancer clinically and radiologically. Only histology will provide the diagnosis.^[2] Surgical excision of the tumor with healthy margins is the only treatment. In the event of incomplete exercise, the risk of local tumor recurrence is accumulated, however without ever leading to metastases.^[2]

2- CLINICAL CASE

Mrs RH, a 54-year-old girl, without any notable pathological history, was followed in our consultation for a right breast nodule since February 2022. The physical examination showed a mass of 3 cm, in the superior-internal quadrant of the right breast, painless, firm, mobile in relation to the two superficial and deep planes and without retraction or nipple discharge, lymph node areas free. A mammography + breast ultrasound was done and objectified breasts of fat density type 3 with focal asymmetry with a lesion of the superior-internal quadrant of the right breast measuring 33 mm Right breast Birads 4 Left breast Birads1.

(Figure 1 +2).

A microbiopsy was performed but came back inconclusive.

A large lumpectomy of the right breast was performed.

The pathological report concluded to a desmoid tumor measuring 2.5*1cm long axis with fuso-cellular proliferation made of elements of variable density arranged in more or less undulating bundles and punctuated by vessels with slightly thickened walls with or without peripheral retraction. The excisional borders were healthy.

Close monitoring was performed, unfortunately the patient was lost to follow-up.

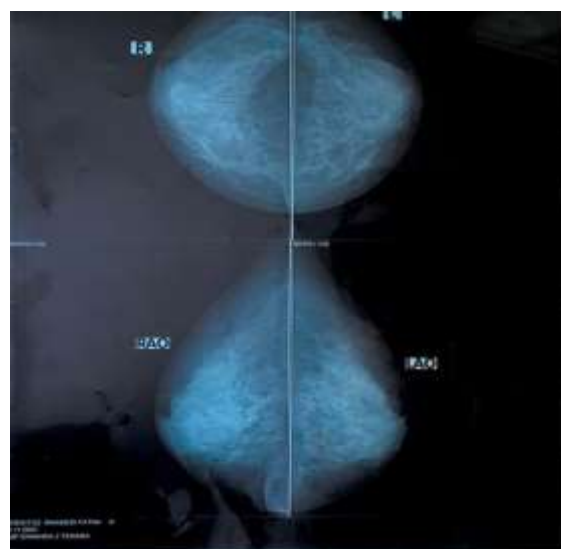


Figure 1: Mammogram Showing The Lesion in The Superior-Internal Quadrant.

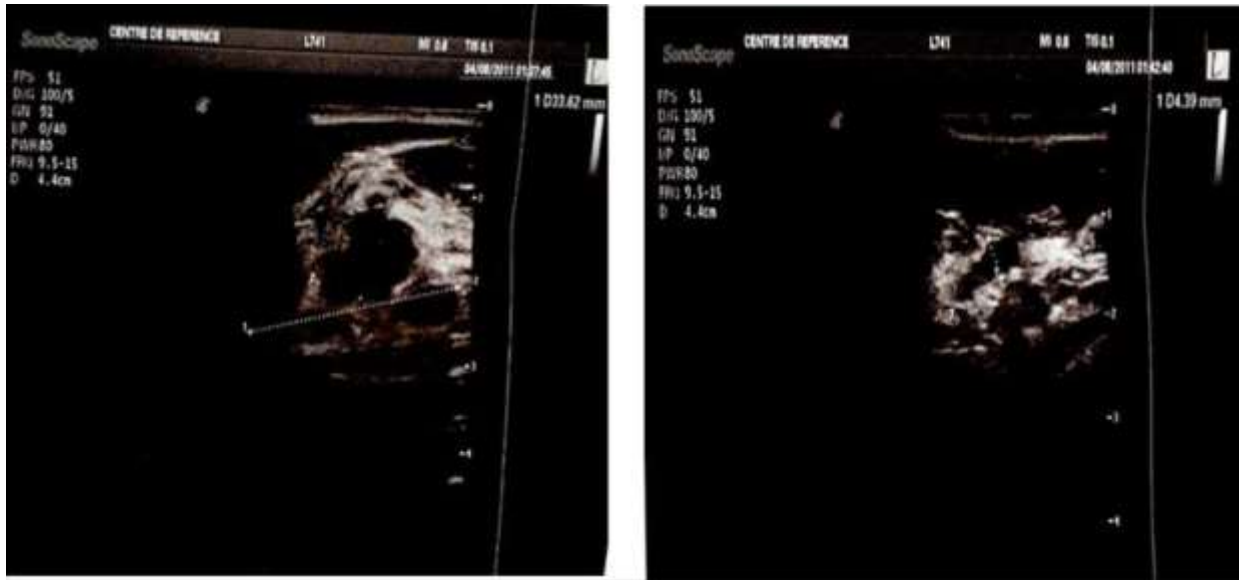

Figure 2: Ultrasound Showing the Lesion in The Superior-Internal Quadrant.

3 DISCUSSION

Desmoid fibromatosis of the breast represents 0.2% of primary breast tumors and 4% of extra abdominal fibromatoses.^[1] It affects women aged between 13 and 80 years with a peak frequency between 30 and 50 years.^[3] Its origin is not well known. Three etiologies are suspected: traumatic, hormonal or hereditary origin. In some cases, a genetic component is present; two percent of these tumors are of genetic origin, by mutation of the adenomatous polyposis coli (APC) gene, and fall within the framework of Gardner syndrome associated with familial adenomatous polyposis (FAP).^[3] Cases have been described after trauma, or after breast surgery such as breast reduction surgery.^[4,5] or after breast prosthesis.^[6,7] Unlike abdominal desmoid tumors, breast fibromatosis does not seem to be associated with pregnancy.^[8] Mammary fibromatosis is a benign tumor of the breast, but its clinical, mammographic and ultrasonographic presentation is often very suspicious.^[9]

Clinically, breast fibromatosis presents as a firm, poorly defined, painless, unilateral nodule of variable size (3 cm on average), more often peripheral than peri-areolar, sometimes associated with skin or nipple retraction. This lesion may be painful, especially if it infiltrates the deep layers. Nipple discharge is rare and patients do not have palpable adenopathy. The involvement may rarely be bilateral. Imaging often takes on the appearance of a malignant tumor. The images observed on mammography are suggestive of a malignant lesion (asymmetry of density, poorly defined opacity with blurred and irregular contours, spicules).

Micro or macrocalcifications are rare and correspond to associated breast lesions. On ultrasound, fibromatosis appears as a solid, spiculated or microlobulated, irregular, hypoechoic mass with posterior attenuation, mimicking a malignant lesion.^[10] Magnetic resonance

imaging is of interest to assess possible parietal invasion.^[7] Although few studies have been performed in MRI for fibromatosis, generally, it is a poorly contoured mass, often spiculated, isointense to the muscles, in iso/hypersignal T2 of variable intensity, and heterogeneous.

The kinetics of enhancement is variable, sometimes with a progressive benign appearance, sometimes more suspicious in plateau, as in our first case, or with a washout.^[5]

The preoperative diagnosis can be evoked at microbiopsy but most often, it is affirmed after diagnostic surgery, which is the case in our first patient. Pathologically, desmoid fibromatosis presents macroscopically as a fairly well circumscribed lesion, with an indurated, fasciculated, pearly consistency and varying in size from 5 to 10 cm in diameter.

Histological examination shows a pauci cellular proliferation with spindle cells. These cells are fibroblastic and myofibroblastic in appearance, arranged in long parallel bundles within a collagen-rich, often wavy background. The cells usually do not show nuclear abnormalities and mitoses are rare.

The poor peripheral limitation with infiltration of the adjacent breast tissue in a finger-like pattern is an important diagnostic feature. There are a few vessels, small and often surrounded by a clear space.

It probably has its indication in case of recurrence and contraindication to surgery or radiotherapy. In conclusion, the clinical, radiological and histological manifestations, and the therapeutic conduct of our two observations were consistent with the literature. It is a very rare pathology that deserves to be studied and known because of its clinical and radiological similarity

with breast cancer. The main treatment is surgery with healthy margins since this tumor has a high potential of recurrence without ever giving metastasis.

Adjuvant treatments are being evaluated due to the small number of patients affected. Both patients are satisfied with the results and are continuing their follow-ups in our outpatient clinic. They have no tumor recurrence to date.

4-CONCLUSION

Breast fibromatosis is a very rare pathology. It must be known because it can mimic, clinically and radiologically, cancer. Wide surgical excision with healthy margins constitutes the only treatment for this pathology whose evolution is mainly characterized by local recurrence. Radiotherapy is reserved for cases of local recurrence when surgery is impossible.

REFERENCES

1. Croce S, Letourneux C, Dale G, Mathelin C. La fibromatose mammaire: une lésion bénigne peu connue. *Gynecol Obstet et Fertil*, 2009 Mai; 37(5): 442–6. [PubMed] [Google Scholar]
2. Amourak S, Alaoui FF, Jayi S, Chaara H, Melhouf MA. Fibromatose desmoïde du sein: à propos d'un cas et une revue de la littérature. *Pan African Medical Journal*, 2015; 21: 1.
3. Desmoid tumor of the breast in a 9 years old little girl 2011, *Annales de Pathologie*.
4. Driss M, Mrad K, Ben Amor H, Abbes I, Sassi S, Ben Romdhane K. Fibromatosis of the breast: clinical and pathology analysis of two cases. *Ann Pathol*, 2002 juin 1; 22(3): 206–9. [Google Scholar]
5. Schwarz GS, Drotman M, Rosenblatt R, Milner L, Shamonki J, Osborne MP. Fibromatosis of the breast: case report and current concepts in the management of an uncommon lesion. *Breast J*, 2006; 12(1): 66–71. [PubMed] [Google Scholar]
6. Janinis J, Patriki M, Vini L, Aravantinos G, Whelan JS. The pharmacological treatment of aggressive fibromatosis: a systematic review. *Ann Oncol*, 2003; 14(2): 181–90. [Abstract] [Google Scholar]
7. [Desmoid tumor of the breast]. Quiel V.
8. *Zentralbl Gynakol*, 122(8): 433-435, 01 Jan 2000
Cited by: 0 articles | PMID: 11005135.
9. Desmoid tumour of the breast: case report and review of the literature. Horevoets J, Smet B, Pattyn P, van Dorpe J, Vuylsteke P *Acta Chir Belg*, 113(4): 304-307, 01 Jul 2013 Cited by: 2 articles | PMID: 24224444.
10. Glazebrook KN, Reynolds CA. Mammary Fibromatosis. *American Journal of Roentgenology*, 2009 sept 1; 193(3): 856–60. [PubMed] [Google Scholar]