

RARE THINGS, DO HAPPEN

Sukhpal Kaur^{*1}, Riponjot Singh² and Ramandeep kaur³

¹Professor, Department of Orthodontics and Dentofacial Orthopaedics, Desh Bhagat Dental College and Hospital, Mandi Gobindgarh. India.

²First Year Undergraduate, BSc Biology, Western University, Canada.

³Ex Lecturer, Department of Orthodontics and Dentofacial Orthopaedics, Desh Bhagat Dental College and Hospital, Mandi Gobindgarh. India.

Corresponding Author: Dr. Sukhpal Kaur

Professor, Department of Orthodontics and Dentofacial Orthopaedics, Desh Bhagat Dental College and Hospital, Mandi Gobindgarh. India.

Article Received on 12/10/2022

Article Revised on 02/11/2022

Article Accepted on 23/11/2022

ABSTRACT

Impaction of maxillary and mandibular canine is a frequently occurring clinical entity and treatment of this usually requires an interdisciplinary treatment plan. Single tooth impactions are common while multiple impactions are rare to occur, usually associated with some systemic disorders. Depending on location and pattern, horizontally and transmigrated canines are uncommon clinical condition. Purpose of this article is to present two cases, one with multiple canine impactions that are bilateral maxillary permanent canine impaction, horizontally impacted mandibular canines with right canine transmigration which is rare to occur and second case shows horizontally impacted transmigrated canine, also rare clinical entity.

KEYWORDS: Impaction, transmigration, bilateral, ectopically positioned.

INTRODUCTION

A tooth is impacted when its eruption is prevented by overlying gum, bone or any other tooth.^[1] Eruption failure is common dental anomaly in permanent dentition. Impacted teeth etiology includes both local and systemic factors. Local factors such as crowding of teeth, ectopically positioned tooth germ, supernumerary teeth, mucosal and bony barrier in path of eruption, retained or premature loss of primary tooth. Systemic factors are heredity, endocrinal diseases, febrile diseases and irradiation exposure.^[2] Eruption of permanent teeth is a complex, genetically based event in which eruptive movement of tooth germ occurs at a predetermined time and route to reach at occlusal level. Because of complexity of eruption process, it may result in some complications such as failure of tooth eruption and retardation of tooth eruption.^[3]

Impacted canine can lead to certain problems such as malpositioning of tooth, internal and external root resorption, migration of adjacent tooth, cyst formation, pain and infection.^[4] Impacted canine can be diagnosed by clinical examination, radiographic examination such as Occlusal films, Panoramic films, cone beam computed tomography etc.

Occasionally tooth travels to other site from its site of development and when it passes through midline of

dental arch, it is called as transmigration. Tarsitano et al defined transmigration as the phenomenon of an unerupted mandibular canine crossing the midline.^[5] Javid expanded this definition, so according to him tooth is considered to be transmigrated even when more than half of the tooth had crossed through the midline.^[6]

CASE REPORT 1

A patient aged 18 years came to department of Orthodontics and Dentofacial Orthopaedics with chief complaint of malalignment of front teeth. Intraoral examination presented Class I molar relation on right side and end on molar relation on left side (Fig.1 and 2). Patient had complete deep bite with 1mm overjet (fig.3). In maxillary arch permanent teeth erupted except right and left canine, right and left third molar, and retained deciduous canine on both right and left side were present. (Fig.4) In mandibular arch clinically missing permanent teeth were both side canines, right and left side third molars and second premolars. Also there was retained deciduous canine on both right and left side and deciduous second molar retained on left side of mandibular arch.(Fig.5)

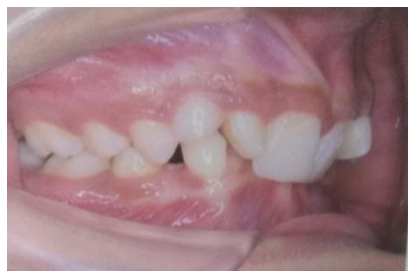

Fig.1: Intraoral right side view.

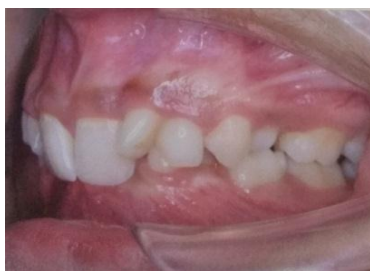

Fig.2: Intraoral left side view.

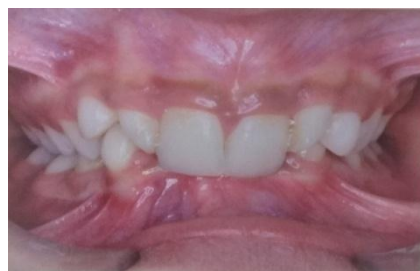

Fig.3: Intraoral frontal view.

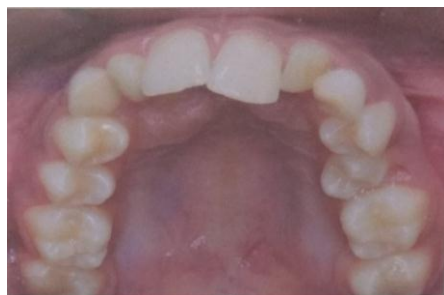

Fig.4: Intraoral maxillary occlusal view.

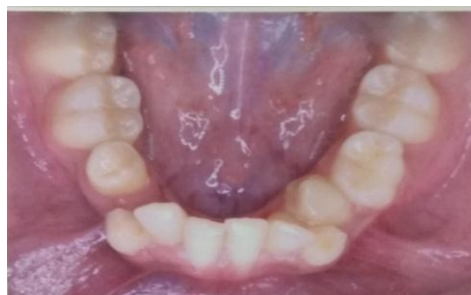

Fig.5: Intraoral mandibular occlusal view

From medical history it was reported that patient is healthy with no systemic problem or syndrome. Also there was no family history for the similar condition. Extra orally Patient had straight, pleasing profile.

Orthopantomogram (OPG) examination revealed right and left permanent impacted canine in maxillary arch. Both mandibular permanent canines were horizontally impacted on left side of mandibular arch. All four third molars and right and left side second mandibular premolars were found to be missing from OPG examination (fig.6).

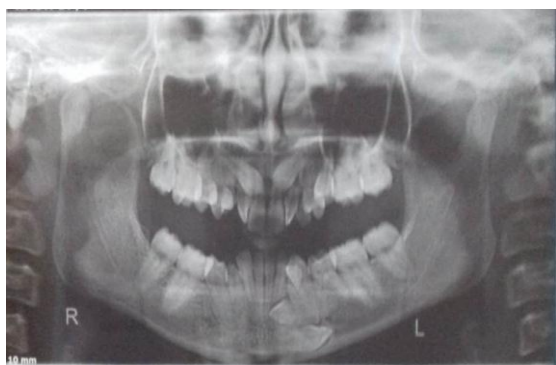

Fig. 6: OPG showing impacted and transmigrated canines and missing teeth.

CASE REPORT 2

Another patient aged 20 years female came to the department with chief complaint of proclined upper teeth. Intra oral examination revealed class I molar relation on right and left side (fig.8 and 9) with increased overjet. In maxillary arch permanent teeth till second molar were present clinically and in mandibular arch permanent teeth till second molar except left side canine were erupted. (Fig.10 and fig.11) Mandibular midline found to be shifted to left side.(Fig.7).

Extra orally patient had convex facial profile, posterior facial divergence and potentially incompetent lips. From medical history it was reported that patient is healthy with no systemic problem or syndrome. Also there was no family history for similar condition.

Orthopantomogram (OPG) examination revealed impacted mandibular left canine which has migrated to right side of arch. It was present near the border of mandible crossing the midline and below the roots of incisors and right canine. Maxillary right third molar was also missing. (Fig.12).

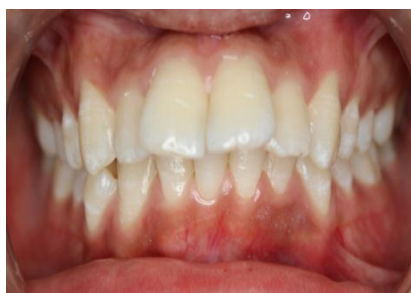

Fig.7: Intraoral right side view.

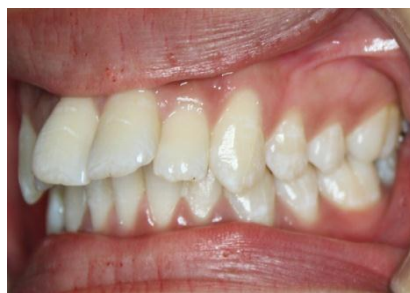

Fig.8: Intraoral left side view.

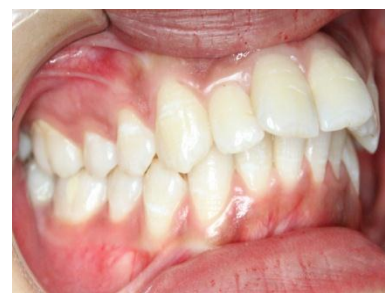

Fig.9: Intraoral frontal view.

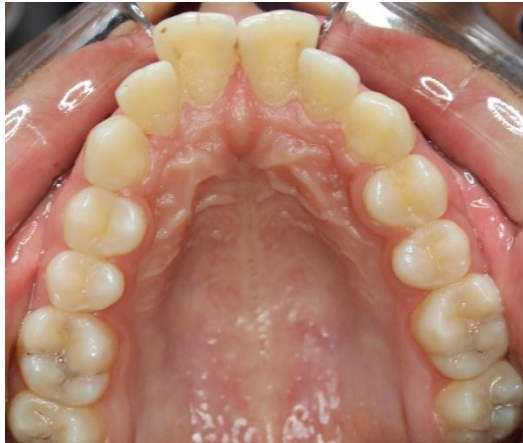

Fig.10: Intraoral maxillary occlusal view.

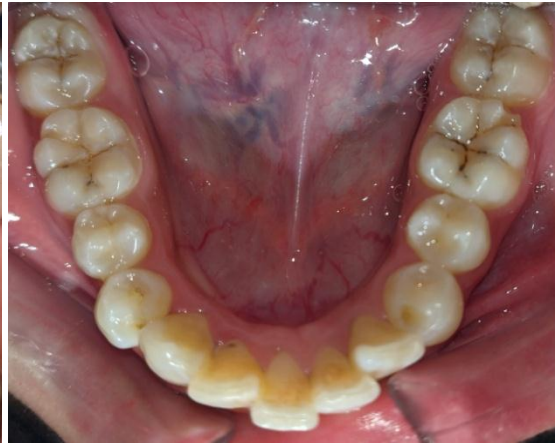


Fig.11: Intraoral mandibular occlusal view

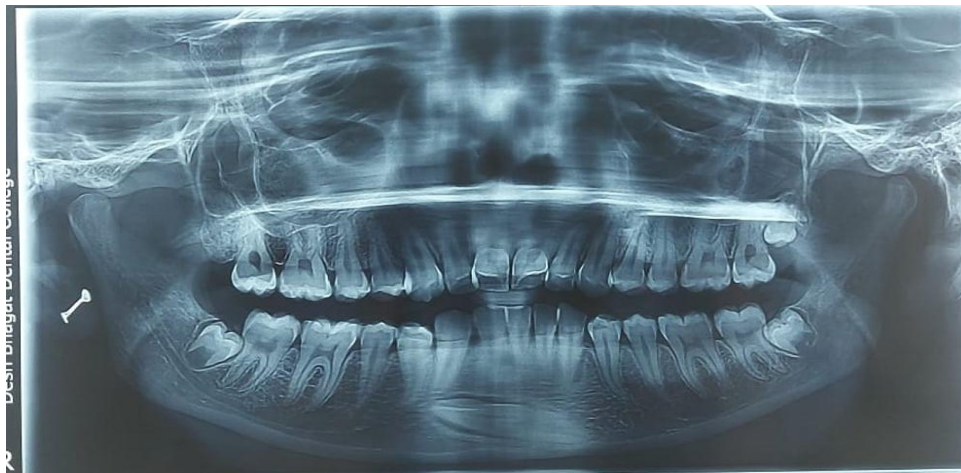

Fig.12: OPG showing impacted and transmigrated left canine.

DISCUSSION

The presented case 1 showed bilateral maxillary and mandibular canine impactions. In mandibular arch both the canines were horizontally impacted on one side of arch, right side canine migrated to left side that is transmigration. Case 2 showed impacted and transmigrated mandibular left canine. For proper treatment planning regarding impacted canines, these were evaluated for their vertical position level, angulation and overlapping with respect to neighboring tooth. For this various classification systems were given.

Classification to determine vertical position in relation to neighboring tooth^[7]

Level A: When impacted canine crown is touching the cervical line of adjacent tooth.

Level B: In this level position of impacted canine lies between cervical line and root apex of adjacent tooth.

Level C: When crown of impacted canine is positioned below root apex of neighboring tooth.

Another classification which determine overlapping of adjacent tooth by impacted canine

Grade 1: Grade 1 shows no overlapping of adjacent tooth by impacted canine,

Grade 2: Here impacted canine overlaps less than half width of root of adjacent tooth.

Grade 3: More than half root width of adjacent tooth is overlapped by impacted canine.

Grade 4: Impacted canine overlaps complete root width of adjacent tooth^[8,9]

According to angulation: This classification is based on angle between long axis of impacted tooth and mid sagittal plane

Impacted canines are classified as vertical (long axis of impacted tooth is almost parallel to mid sagittal plane or at an angulation of 0-15 degrees), mesioangular (long axis directed towards mid sagittal plane with angle of 15-70 degrees), distoangular (long axis directed away from mid sagittal plane and forming an angle above the apical area of impacted canine) and horizontal (angle between long axis of impacted tooth and mid sagittal plane is more than 70 degrees).^[10]

Mupparapu's classification for transmigrated teeth^[11]

Type I: Mesioangularly canine positioned across the midline and it may be positioned labial or lingual to the anterior teeth.

Type II: Horizontally impacted canine lying near the inferior border of the mandible inferior to the root apices of the incisor teeth.

Type III: Erupting canine on the contra lateral side of dental arch.

Type IV: Horizontally impacted canine below the root apices of posterior teeth and located near the inferior border of the mandible.

Type V: Vertically positioned canine in the midline with the long axis of the tooth crossing the midline.

In present case report 1 the maxillary canine were classified as in level B, grade 4 as canines are completely overlapping lateral incisor roots, and mesioangular in position. Mandibular transmigrated canine falls in Type IV as it is positioned horizontally, near the inferior border of mandible in premolar area. Patient also had agenesis of all third molars and Mandibular right and left side second premolars.

In Case report 2 impacted mandibular canine came under Type II of Mupparapu's classification that is horizontally impacted canine near border of mandible.

Maxillary impaction is more common than mandibular canine impaction. Rohrer observed prevalence of maxillary canine impaction is 20 times more than mandibular canine impaction. Maxillary canine prevalence was 2.06% and mandibular prevalence was 0.1%.^[12] Lower prevalence for mandibular canine impaction was also reported by various other studies: Chu et al^[13] observed 0.07%, Aydin et al^[14] reported 0.44% prevalence in Turkish population, Jain et al reported 0.37% prevalence in Indian population.^[10] Chu et al^[13] reported higher prevalence for maxillary canine that is 2.1%, Jain et al reported prevalence of 0.94%^[10] Dachi and Howell reported higher incidence of 0.92% for maxillary canine impaction than mandibular canine impaction incidence of 0.38%.^[15] Similarly Grover and Lorton found greater incidence for maxillary canine impaction (2.39%) and less for mandibular canine impaction (0.22%).^[16]

Mandibular canine impacted in horizontal position is rare condition and its transmigration is even rarer phenomenon.^[17,18,19] Javid reported only one transmigrated mandibular canine in 1000 individuals.⁶ Zvolanek found no case of mandibular transmigrated canine.^[20] Unilateral transmigration is more common but cases of bilateral transmigration were also found by many authors.^[21-24]

Exact etiology of transmigration of canine is still not known.^[25] Some possible causative factors considered for transmigration are: Congenital factors, prolonged retention of deciduous tooth, crowding, premature loss of deciduous tooth, increased crown length of mandibular canine, tumors, cysts and odontomes positioned in the path of eruption resulting malposition of tooth^[26-29] Some other etiological factors reported by other studies are: tooth germ position abnormality^[30], embryonic life displacement of dental lamina.^[31,32] agenesis of adjacent teeth.^[33] Most of studies reported that left canine

transmigration is more common.^[11,25,28,29,34] From previous studies it was reported that out of 127 cases of canine transmigration, 45.6% cases fall into Type I, 20% into Type II, 14% into type III, 17% into type IV and 1.5% into type V.^[12] Another study reported 3 cases of type I, 2 cases of type II, 1 case each of type IV and type V and no case of type III.^[35] Therefore type I is more common to occur.

Impaction of canine may be unilateral or bilateral. Occurrence of bilateral maxillary impactions was found to be in the range of 8%-10% of impactions.^[36] Other studies reported higher prevalence of unilateral canine impaction.^[10,15] Patil et al in their study observed that 6% of patients with bilateral impactions and 94% showed unilateral impactions.^[37] Similar findings were observed by Hameedullah et al (87.5%) and Oliviera et al (99.2%).^[38,39]

Treatment options available for impacted teeth include surgical removal of tooth, transplantation, exposure and alignment with fixed orthodontic treatment. To choose appropriate treatment option, precise diagnosis and treatment planning is required. Thoma suggested surgical removal of transmigrated canine. Fiedler and Alling also recommended surgical removal of transmigrated canines.^[40] Transplantation may be carried out when sufficient space for canine is available.^[41] Orthodontic alignment of labially impacted transmigrated tooth may be carried out. But if crown of transmigrated canine crossed opposite incisor area or its apex migrates past the apex of adjacent lateral incisor, in such conditions, it may be impossible to bring the tooth into its correct position.^[42]

Tooth agenesis is the common dental anomaly with high frequency in the world's population. It is more common in permanent dentition than primary dentition. Tooth agenesis prevalence varies from 2.2 to 10.1%. The prevalence, pattern and distribution of congenitally absent teeth is found to be variable among different population. The higher prevalence was observed in Australian Caucasians that is 6.3%, followed by the European Caucasians 5.5% and North American Caucasians showed prevalence of 3.9%.^[43] Polder reported that dental agenesis is 1.37 times higher in females than in males. Mandibular second premolars were found to be most affected, followed by maxillary lateral incisors and maxillary second premolars.^[44,45]

It is very less common to have all four permanent canines impacted in a healthy individual with no associated systemic problem as in case report 1 and also the pattern for impactions in this presented case is not common that was horizontally impacted mandibular canine, right canine transmigration and bilateral impacted maxillary canines. Also this patient had missing all four third molars, right and left second mandibular premolars. All these findings together making this case an uncommon clinical entity. The case

report 2 has horizontally impacted and transmigrated mandibular canine which is also very uncommon situation. For treatment of such cases, some more investigations are needed such as occlusal film, intra oral radiograph and cone beam computed tomogram etc to know the exact position of impacted teeth and their relation to adjacent structures and to make precise diagnosis and treatment planning. There are various factors which are considered for successful management of impacted teeth, these include position and direction of impacted tooth, status of root formation, dilacerations and space available for impacted tooth.^[46,47]

CONCLUSION

Maxillary canine impactions are more common than mandibular impactions. Among maxillary impactions, unilateral canine impactions have high occurrence as compared to bilateral impactions. Horizontal mandibular impaction is rare and transmigration is further rarest phenomenon. Impacted canine always remains a challenge to an orthodontist. Proper diagnosis and treatment planning is needed for it and maximum efforts should be made to bring this tooth in its normal position as canine is important tooth for occlusion and maintaining esthetics. There is need to report more such cases which will help in further elaborate discussion of diagnosis and treatment planning for such challenging cases.

REFERENCES

- Bhat M, Hamid R, Mir A. Prevalence of impacted teeth in adult patients: A radiographic study. *International Journal of Applied Dental Sciences*, 2019; 5(1): 10-12.
- Kaur S, Singh R. Rare occurrence of impacted and inverted maxillary third molar- A case report. *Int J Curr Res Med Sci.*, 2018; 4(4): 53-55.
- Patil S, Maheshwari S. Prevalence of impacted and supernumerary teeth in North Indian population. *J Clin Exp Dent.*, 2014; 6(2): e116-e120.
- M Ranjit et al. Impacted canines: Etiology, diagnosis and orthodontic management. *J Pharm Bioallied Sci.*, 2012, Aug; 4(2): S234-S238.
- Tarsitano JJ, Wooten JW, Burditt JT. Transmigration of unerupted mandibular canines: Report of cases. *J Am Dent Assoc*, 1971; 82(6): 1395-7.
- Javid B. Transmigration of impacted mandibular cuspids. *Int J Oral Surg.*, 1985; 14(6): 547-9.
- Yavuz MS, Aras MH, Büyükkurt MC, Tozoglu S. Impacted mandibular canines. *J Contemp Dent Pract*, 2007; 8: 78-85.
- Stivaros N, Mandall NA. Radiographic factors affecting the management of impacted upper permanent canines. *J Orthod*, 2000; 27: 169-173.
- Power SM, Short MB. An investigation into the response of palatally displaced canines to the removal of deciduous canines and an assessment of factors contributing to favourable eruption. *Br J Orthod*, 1993; 20: 215-223.
- Jain S, Debbarma S. Patterns and prevalence of canine anomalies in orthodontic patients. *Medicine and Pharmacy Reports*, 2019; 92(1): 72-78.
- Mupparapu M. Patterns of intra-osseous transmigration and ectopic eruption of mandibular canines: review of literature and report of nine additional cases. *Dentomaxillofac Radiol*, 2002; 31: 355-360.
- Röhrer A. Displaced and impacted canines A radiographic research. *International Journal of Orthodontia, Oral Surgery and Radiography*, 1929; 15: 1003-1020.
- Chu FC, Li TK, Lui VK, Newsome PR, Chow RL, Cheung LK. Prevalence of impacted teeth and associated pathologies--a radiographic study of the Hong Kong Chinese population. *Hong Kong Med J.*, 2003; 9: 158-63.
- Aydin U, Yilmaz HH, Yildirim D. Incidence of canine impaction and transmigration in a patient population. *Dentomaxillofac Radiol*, 2004; 33: 164-169.
- Dachi SF, Howel FV. A survey of 3874 routine full mouth radiographs II. A study of impacted teeth. *Oral Surg Oral Med Oral Pathol*, 1961; 14: 1165-69.
- Grover P, Lorton L. The incidence of unerupted permanent teeth and related clinical cases. *Oral Surg Oral Med Oral Pathol*, 1985; 59(4): 420-425.
- Thoma KH. *Oral Surgery*. 2nd ed. St. Louis, Missouri: CV Mosby, 1952.
- Miranti R, Levbarg M. Extraction of a horizontally transmigrated impacted mandibular canine: Report of case. *J Am Dent Assoc*, 1974; 88(3): 607-10.
- Shapira Y, Mischler WA, Kufinec MM. The displaced mandibular canine. *ASDC J Dent Child*, 1982; 49: 362-4.
- Zvolanek JW. Transmigration of an impacted mandibular canine. *Illinois Dental Journal*, 1986; 55(2): 86-87.
- Auluck A, Nagpal A, Setty S, Pai KM, Sunny J. Transmigration of impacted mandibular canines- Report of four cases. *J Can Dent Assoc*, 2006; 72: 249-52.
- Joshi MR. Transmigrant mandibular canines: A record of 28 cases and a retrospective review of the literature. *Angle Orthod*, 2001; 71: 12-22.
- Rebellato J, Schabel B. Treatment of a patient with an impacted transmigrant mandibular canine and a palatally impacted maxillary canine. *Angle Orthod*, 2003; 73: 328-36.
- Büyükkurt MC, Aras MH, Caglaroglu M, Gungormus M. Transmigrant mandibular canines. *J Oral Maxillofac Surg*, 2007; 65: 2025-9.
- Camilleri S, Scerri E. Transmigration of mandibular canines—a review of the literature and a report of five cases. *Angle Orthodontist*, 2003; 73: 753–762.
- Al-Waheidi E M H. Transmigration of unerupted mandibular canines: a literature review and a report

- of five cases. *Quintessence International*, 1996; 27: 27–31.
27. Ando S, Aizawa K, Nakashima T, Sanka Y, Shimbo K, Kiyokawa K. Transmigration process of impacted mandibular cuspid. *Journal of Nihon University School of Dentistry*, 1964; 6: 66–71.
 28. Shapira Y, Kuftinec M M. Intrabony migration of impacted teeth. *Angle Orthodontist*, 2003; 73: 738–743.
 29. Peck S. On the phenomenon of intraosseous migration of nonerupting teeth. *American Journal of Orthodontics and Dentofacial Orthopedics*, 1998; 113: 515–517.
 30. Alaejos-Algarra C, Berini-Aytes L, Gay-Escoda C. Transmigration of mandibular canines: Report of six cases and review of the literature. *Quintessence Int.*, 1998; 29(6): 395-8.
 31. Mitchell L. Displacement of a mandibular canine following fracture of the mandible. *Br Dent J.*, 1993; 174(11): 417-8.
 32. Nixon F, Lowey MN. Failed eruption of the permanent canine following open reduction of a mandibular fracture in a child. *Br Dent J.*, 1990; 168(5): 204-5.
 33. Vichi M, Franchi L. The transmigration of the permanent lower canine. *Minerva Stomatol*, 1991; 40(9): 579-89.
 34. Camilleri S. Double transmigration and hyperdontia. *Angle Orthod*, 2007; 77: 742–744.
 35. Agarwal S, Garg A, Agarwal SS. Prevalence and pattern of transmigration of impacted canines: A retrospective study. *JDOR*, 2015; 11(1): 26-31.
 36. Mulick JF. Dr. James F. Mulick on impacted canines. *J Clin Orthod*, 1979; 13: 824-34.
 37. Patil S, Maheshwari S, Santosh BS, Khandewal S. Prevalence of impacted canines in population of Western Part of India. *Universal research Journal Of Dentistry*, 2014; 4(3): 148-152.
 38. De Oliviera DL, Zorzetto DL, Marzola C, Toledo-Filho JL, Barbosa JL, Haagsma IB. Impacted canine prevalence in Curitiba city-PR. *Revista ATO*, 2008; 8: 94-108.
 39. Jan H, Anwar A, Naureen S. Frequency of impacted canines in orthodontic patients presenting to armed forces institute of dentistry. *Armed Forces Institute of Dentistry*, 2009; 4: 79-82.
 40. Fiedler LD, Alling CC. Malpositioned mandibular right canine: report of case. *J Oral Surg*, 1968; 26: 405–407.
 41. Howard RD. The anomalous mandibular canine. *Br J Orthod*, 1976; 3: 117–121.
 42. Wertz RA. Treatment of transmigrated mandibular canines. *Am J Orthod Dentofacial Orthop*, 1994; 106: 419–427.
 43. Bozga A, Stanciu RP, Manuc D. A study of prevalence and distribution of tooth agenesis. *J Med Life.*, 2014; 7(4): 551-554.
 44. Polder BJ, Van't Hof MA, Van der Linden FPGM, Kuijpers-Jagtman AM. A meta-analysis of the prevalence of dental agenesis of permanent teeth. *Community Dentistry and Oral Epidemiology*, 2004; 32: 217–226.
 45. Sisman Y, Uysal T, Gelgor IE. Hypodontia. Does the prevalence and distribution pattern differ in orthodontic patients? *Eur J Dent.*, 2007; 1: 167–173.
 46. Kaur S, Singh R, Soni S, Prashar A. Impacted incisor-A rare finding. *Annals of Geriatric Education and Medical Sciences.*, 2017; 4(1): 29-30 29.
 47. Soni S, Kaur M, Singh R, Kaur S. bilaterally impacted maxillary canines and premolars- A rare case report. *Int. J. Curr. Res. Med. Sci.*, 2017; 3(9): 58-60.