

## PRATISARANIYA KSHARA KARMA IN THE MANAGEMENT OF GARBHASHAYA GREEVAMUKHAGATA VRANA W.S.R. TO CERVICAL EROSION-A PARA SURGICAL TECHNIQUE

Dr. Shafiqul Aziz Khan\*<sup>1</sup> and Dr. Papiya Jana<sup>2</sup>

<sup>1</sup>PG Scholar, Department of Prasuti Tantra Evam Stree Roga, Sri Kalabyraveshwara Swamy Ayurvedic Medical College, Hospital and Research Centre, Bangalore, Karnataka, India.

<sup>2</sup>Professor, Department of Prasuti Tantra Evam Stree Roga, Sri Kalabyraveshwara Swamy Ayurvedic Medical College, Hospital and Research Centre, Bangalore, Karnataka, India.

**Corresponding Author: Dr. Shafiqul Aziz Khan**

PG Scholar, Department of Prasuti Tantra Evam Stree Roga, Sri Kalabyraveshwara Swamy Ayurvedic Medical College, Hospital and Research Centre, Bangalore, Karnataka, India.

Article Received on 11/07/2022

Article Revised on 01/08/2022

Article Accepted on 21/08/2022

### ABSTRACT

Cervical erosion is one of the commonest gynaecological diseases which includes large section of women among reproductive age group and needs medical attention. It is asymptomatic in many of the cases but sometimes presents with symptoms like white discharge, itching vulva, dyspareunia etc.<sup>[1]</sup> It adversely affects the physiological & psychological health of women. In modern system its treatment done with diathermy and cryosurgery which has various side effect like cervical stenosis, accidental burns, etc. Cervical erosion can be understood as *Garbhashaya greevamukhagata Vrana* as it resembles the features of *Vrana* as explained in the classics. In *Ayurvedic* classics no direct description of *Garbhashaya greevamukhagata Vrana* is available but *Ashtanga Sangraha* has described it in reference of *Yoni Vranekshana Yantra* considering the features of cervical erosion, which occurs at *greevamukha* of *Garbhashaya*.<sup>[2]</sup> For the management of *vrana* Acharya Sushruta has explained *Kshara karma*, one among *shashti upakramas*, which is a para surgical technique.<sup>[3]</sup> Using *Yava kshara* which is having properties like *lekhana*, *sodhana*, *ropana*, *stambhana* and specially *kaphghna* found to be useful. Here is a case study with diagnosis of *garbhashaya greevamukhagata vrana* w.s.r. to cervical erosion and its successful management with *pratisaraniya kshara karma*.

**KEYWORDS:** *Garbhashaya greevamukhagata vrana*, *pratisaraniya kshara karma*, cervical erosion.

### INTRODUCTION

Cervical erosion can be understood as *Garbhashaya greevamukhagata Vrana* as it resembles the features of *Vrana* explained in the classics.<sup>[1]</sup> In *Ayurvedic* classics no direct description of *Garbhashaya greevamukhagata Vrana* is available but *Ashtanga Sangraha* has described it in reference of *Yoni Vranekshana Yantra* that suggests presence of *yoni vrana*.<sup>[2]</sup> Cervical erosion or ectropion is a benign condition where the squamous epithelium of the ectocervix is replaced by columnar epithelium which is continuous with the endocervix.<sup>[3]</sup> About 85% women suffer from the cervical erosion i.e. benign condition of female genital tract during their lifetime.<sup>[4]</sup> Cervical erosion many a times can be associated with white vaginal discharge and back pain. Application of *Yava Kshara* one of the para surgical technique in *Ayurveda* facilitates removal of unhealthy columnar epithelium and growth of new healthy stratified squamous epithelium thus maintaining its integrity and use of *Ayurvedic* medications give symptomatic relief to the patient having cervical erosion.

### CASE STUDY

A female patient aged 32, moderately built, well nourished with married life of 7years having obstetric history of P1L1A0D0, came with complaints of white discharge per vagina since 3months. The patient had associated complaints of lower back pain since 2 months.

She doesn't have any systemic illness.

Her vaiktika and kula vrittana are not significant.

#### Vaiyaktika Vrutanta

Diet – Mixed  
Appetite –Reduced/Poor  
Bowel – once a day, Regular  
Micturition – 4-5 times/day  
Sleep – Sound  
Habits – nil

#### Rajo Vrutanta

Age of Menarche –14years

**Menstrual History:**

- Nature : Regular
- Bleeding duration: 3-4 days
- Interval: 28-30 days

Dysmenorrhoea- absent

Colour- reddish

Clots-absent

Foul smell- Absent

D1 = 2-3 pad, fully soaked

D2 = 2-3pads, fully soaked

D3 = 1-2 pads, partially soaked

D4= 1pad

LMP:05/04/2022

**Obstetric history:** PIL1A0D0

PIL1- 6years, female, FTND

**General Examination**

- Built – moderate
- Nourishment – well
- Pallor – absent
- Oedema – Absent
- Clubbing – Absent
- Cyanosis – Absent
- Icterus – Absent
- Lymphadenopathy – Absent
- Height – 5ft
- Weight –55kg
- BMI –23.7kg/m<sup>2</sup>
- Pulse Rate – 78 beats/minute
- BP – 110/70 mm Hg
- Respiratory Rate – 18/minute
- Heart Rate – 78 bpm
- Temperature – 98°F
- Tongue – uncoated

**Dashavidha Pareeksha**

- Prakruti- Pitta vata
- Vikruti- kapha pradhana vata
- Dosha –kapha pradhana vata
- Dushya –Rasa, Rakta, arthava
- Desha – Sadharana
- Bala – Madhyama
- Sara – Madhyama
- Samhanana –Madhyama
- Pramana – Madhyama
- Satmya – vyamishra
- Satva\_– Madhyama
- Ahara shakti –
- Abhyavarana shakti : avara
- Jarana shakti: avara
- Vyayama shakti – madhyama
- Vaya– Madhyama

**Athura Bhoomi Desha Pariksha**

§Jatataha – Sadharana

§Samvrddhataha – Sadharana

§Vyadhitaha – Sadharana

**Systemic Examination****Respiratory System**

Inspection: Shape of the chest - Bilaterally Symmetrical  
Chest movements - Symmetrical

RR- 18/min

Palpation: Trachea – Centrally placed

Percussion: Resonant over the lung field except cardiac dullness.

Auscultation: Bilateral NVBS heard

**Cardiovascular system**

Inspection: No distended vessels over neck or chest.

Percussion: Cardiac dullness present on left side.

Auscultation: S<sub>1</sub> S<sub>2</sub> heard,

No murmurs heard.

**Central Nervous System**

Patient is conscious well oriented to time, place and person.

**Per Abdomen Examination****• Inspection**

Contour – Round

Umbilicus – Centrally placed, Inverted

**• Palpation**

Soft, Tenderness in supra pubic, left and right iliac fossa  
No organomegaly observed

**• Percussion**

NAD

**• Auscultation**

Normal Bowel sounds heard

**Gynaecological Examination****Examination of Vulva****Inspection**

Pubic Hair – Normal

Clitoris – Normal

Labia – Normal

Discharge –White discharge ++

Discharge - thin in consistency

**Palpation-** No palpable mass observed

**Per Vaginal Examination**

**Cx-** Posterior

Multiparous os, fornices are free, no cervical motion tenderness.

**P/S-Cx-** Unhealthy with 95% of erosion and inflammatory changes.

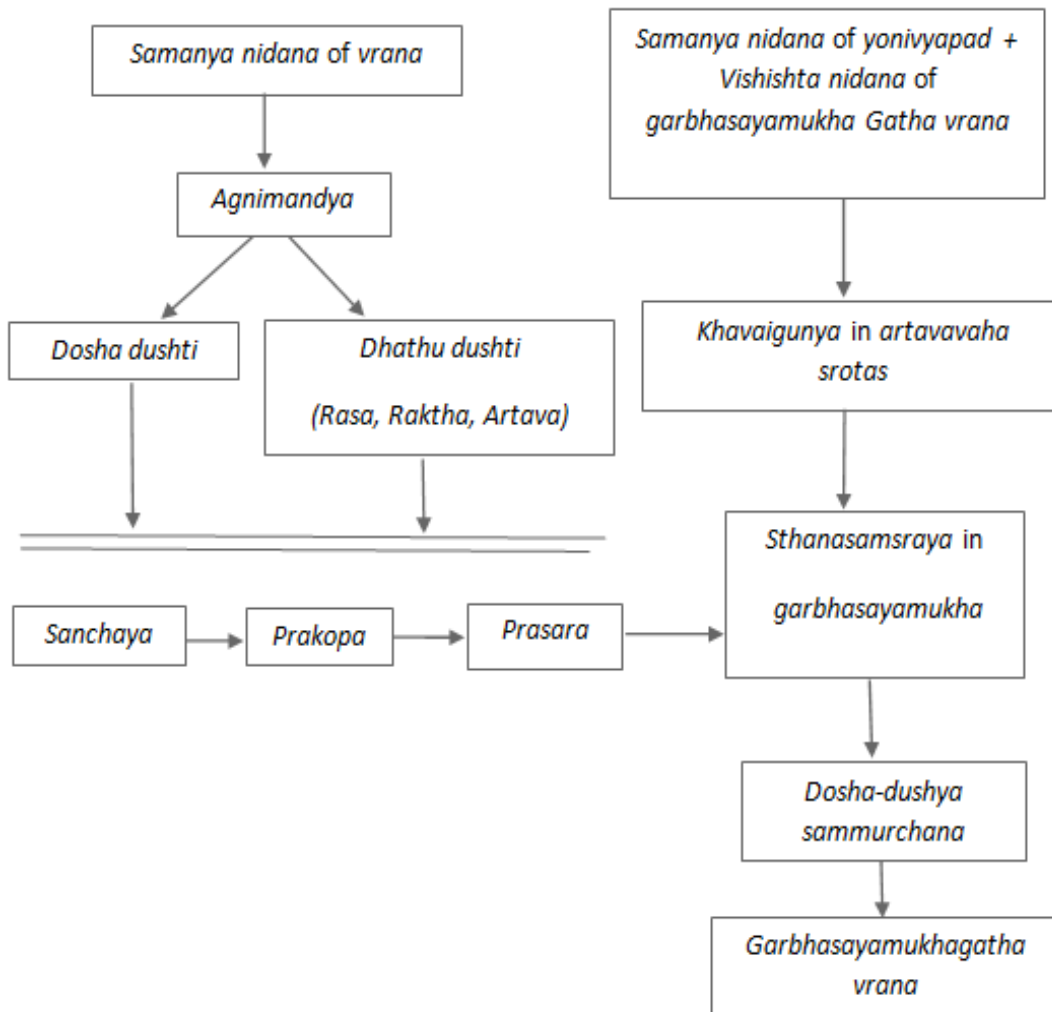
**Investigations:** Pap smear- negative for malignancy, but shows dense inflammatory changes.

**Roga Pareeksha****Nidana**

- Ahara– mithya ahara, vishama bhojana
- Viharaja – ati chintana, diwaswapna
- Roopa- Shweta and pandura srava P/V

- Upashaya- Kashaya rasa pradhana ahara and aushadha.

**Samprapti**



**Samprapti Ghataka**

- Dosha – kapha pradhana vata
- Dushya - Rasa, Rakta, arthava
- Srothas - Rasavaha, Raktavaha, Artavaha srotas
- Sroto dusti – atipravrutti
- Agni – Jataragni and Dhatvagni
- Sanchara sthana - Yoni pradesha
- Vyaktha sthana –Garbhashaya greeva mukha
- Adhithana – Yoni, Garbhashaya
- Vyadhimarga – Abhyantara

- Sadyasadhyata– Sadhya

**Vyavachedaka Nidana**

- Paripluta
- Sleshmaja yonivyapad,
- Garbhashaya greevamukha gata vrana

**Vyadhi Nirnaya**

- Garbhashaya greevamukha gata vrana (cervical erosion)

**Treatment Given**

Treatment	Dose	Duration
Yoni Prakshalana with Triphala+ Panchavalkala Kwatha		7days
Yoni Pichu with Kasisadi Taila	-	7days
Matra Basti with Mahanarayana Taila	60mL	7days

Observation	Results
After 7Days of treatment the patient’s white discharge per vaginum reduced significantly. Symptomatic relieve was observed.	Reduction in the circumference of cervical erosion was noted from 95% to 35% after 7days of treatment.

## DISCUSSION

Garbhashaya greevamukhagata vrana presents with symptoms like white discharge per vagina associated with mild to moderate lower back pain. The treatment to control the white discharge is achieved by use of medicines which are having Kashaya rasa and grahi guna. In this case the use of Chandraprabha vati and pushyanuga curna have shown effective result in treating the white discharge. Chandraprabha vati contains chitraka, pippali, chavya. Vidanga. Maricha, and Shunti which are having deepana and pachana action thus corrects the agni thereby it helps in the restoring the normal function of rasa and rakta dhatu which are seen deranged in this condition. Pushyanuga curna contains patha. Jumbovasthi. Shilodbhava. Ambastha, mocha rasa, samanga, lodhra which are having Kashaya rasa and grahi thus corrects the excessive vaginal discharge. It also contains gairika that corrects the rakta and artava dushti. Lower back ache was relieved by administration of matra basti with dhanawantaram thailam which is vatahara.

Ayurvedic texts have emphasized the use of kshara in vrana cikitsa in the context of shasti upakrama. Pratisaraniya *Kshara* prepared with medicinal drugs like yava, chitraka. Apamarga have *Vrana Shodhana, Ropana* and *Prasadana* properties which yield good results in healing the wound when applied locally over the affected tissues.

Treatment plan for *Garbhashaya Grivamukha Gata Vrana* with *Yava kshara* shows *Lekhana, Sravahara, Shothahara* and *Vranaropana properties*. Hence the case was treated successfully.

## CONCLUSION

Garbhashaya Grivamukha Gata Vrana can be managed well with the application of Yava Kshara along with the use of Ayurvedic medicines that can relieve the associated symptoms significantly.

## REFERENCES

1. Sushruta Samhita of Mahrshi Sushruta, Chikitsa Sthana 1/8, edited with Ayurveda-Tattva-Sandipika Hindi Commentary, scientific analysis, notes etc. by Kaviraja Ambikadutta Shastri, Reprint edition: Chaukhambha Bharti Academy, Varansi, 2006; 1.
2. Vagbhata, Ashtanga Samgraha Vol.1, Sutra Sthana 34/9, with Hindi Commentary by Kaviraj Atrideva Gupta foreword by Rajvaidya Pandit Sri Nandakishor Sharma Bhisagacharya, Chaukhambha Krishnadas Academy, Reprinted, 2005.
3. Padubidri, Daftary. Howkin's & Bourne Shaw's Textbook of Gynaecology. New Delhi: Elsevier, 2013.
4. Neelam et al, management of cervical erosion, AYU Journal, 2009; 30(2): 171-174.