

## UTERINE ADENOSARCOMA (INDIVIDUAL CASE STUDY)

\*<sup>1</sup>El Koummi Jihad, <sup>2</sup>Youssef Nabila, <sup>3</sup>Mokhlis Sabah, <sup>4</sup>Benhessou Mustapha, <sup>5</sup>Ennachit Mohamed, <sup>6</sup>EIKarroumi Mohamed

<sup>1,2,3</sup>Resident in Gynecology Obstetric, CHU IBN Rochd Casablanca Morocco.

<sup>4,5,6</sup>Professor of Gynecology Obstetric, CHU IBN Rochd Casablanca Morocco.

**Corresponding Author: El Koummi Jihad**

Resident in Gynecology Obstetric, CHU IBN Rochd Casablanca Morocco.

Article Received on 21/03/2021

Article Revised on 11/04/2021

Article Accepted on 31/05/2021

### ABSTRACT

Uterine adenosarcoma is an extremely rare tumor (8% of uterine sarcomas), characterized by a proliferation, malignant mesenchymal and benign epithelial. It is recognized by its difficult diagnostic and therapeutic management. Its prognosis is relatively favorable. The objective of this study is to report the clinical aspects and the therapeutic modalities of a case of uterine adenosarcoma revealed by postmenopausal metrorrhagia in a 63-year-old patient, treated for luberkunian adenocarcinoma of the colon. Examination of the patient revealed a polyploid formation delivered through the uterine cervix. Biopsy curettage of the endometrium revealed the presence of a uterine adenosarcoma. Pelvic MRI showed a uterine lesion process infiltrating the myometrium by more than 50%. The treatment was essentially surgical.

**KEYWORDS:** Adenosarcoma, Uterus, Hysterectomy.

### INTRODUCTION

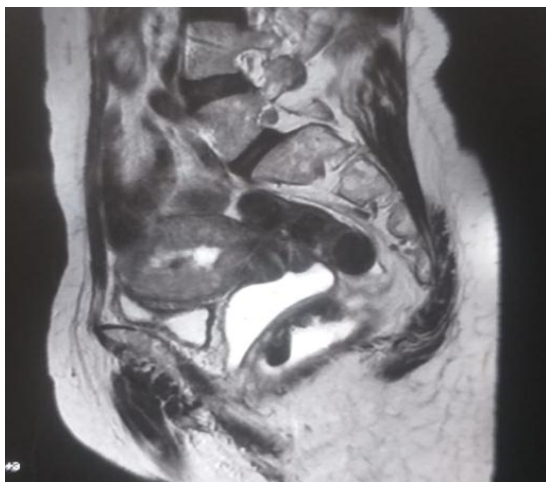
The term adenosarcoma, first described in 1974 by Clement and Sully, refers to a tumor of biphasic nature, associating a benign glandular and malignant sarcomatous contingent.<sup>[1]</sup>

It is considered as a tumor with low malignant potential, whose prognosis is conditioned by the character of the sarcomatous component.<sup>[2]</sup> Its treatment is essentially surgical.<sup>[3]</sup> Survival can be up to 5 years in 80% for stage I adenosarcomas.<sup>[4]</sup>

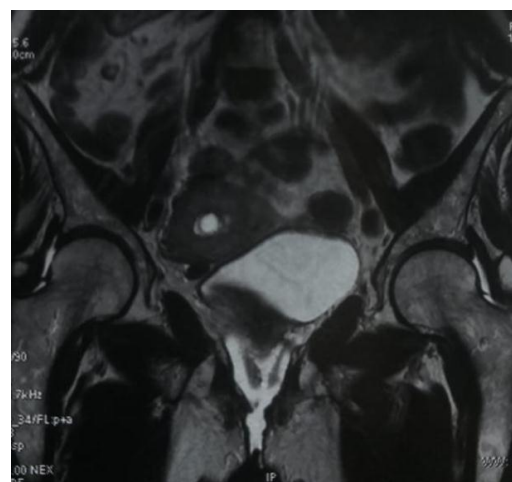### OBSERVATION

Mrs. A.Z, 63 years old, menopausal for 13 years, never took contraception, followed for luberkunian adenocarcinoma of the colon (right colectomy + adjuvant chemotherapy with capecitabine (Xeloda\*) and bevacizumab (Avastin\*), consulted for postmenopausal metrorrhagia. The gynecological examination revealed an enlarged uterus with, on examination under speculum, a polyp delivered through the cervix. The endovaginal ultrasound showed a globular uterus measuring 11.7 cm in long axis with a thickened endometrium, discretely heterogeneous, with cystic areas, hyper vascularized on Doppler color measuring 55 mm. Anathomopathological examination of the polyp was without abnormalities while biopsy curettage of the endometrium under hysteroscopy revealed a malignant mesenchymal tumor

proliferation compatible with endometrial adenosarcoma. Pelvic MRI showed 13 mm inhomogeneous thickness of the endometrium, in T1 inhomogeneous hyposignal, T2 inhomogeneous hypersignal, poorly enhanced after gadolinium injection, with infiltration of the anterofundal wall over 50% (picture 1, 2). The management consisted of total hysterectomy with bilateral adnexectomy and pelvic curage. Pathological examination of the operative specimens confirmed the diagnosis of uterine body adenosarcoma infiltrating less than 50% of the myometrium, with negative pelvic curage. The patient did not receive any adjuvant treatment, and the 3-year surveillance did not reveal any signs of locoregional or distant recurrence.



Picture 1:



Picture 2:

## DISCUSSION

Adenosarcoma is uncommon combined neoplasm, mesenchymal and epithelial. It represents 8% of all uterine sarcomas.<sup>[5,6]</sup>

These tumors are composed of benign epithelial elements, most often of the endometrioid type, and malignant mesenchyme, generally of low grade, which often determines the clinical behavior of these tumors.<sup>[7,8,9,10]</sup>

Only a hundred cases have been described in the literature,<sup>[10]</sup> classifying this tumor as a postmenopausal cancer, with an average age of occurrence of 58 years.<sup>[11]</sup>

The risk factors are unknown. However, an association with previous pelvic irradiation, long-term estrogen use and prolonged exposure to Tamoxifen has been described.<sup>[1,12,13]</sup> Our patient did not have any of these risk factors.

The clinical symptoms are polymorphic, mainly metrorrhagia.<sup>[8]</sup> Other non-specific indicators such as pelvic pain, vaginal discomfort or recent prolapse may be the cause of the medical consultation.<sup>[5,14,15]</sup> Our patient suffered from isolated postmenopausal metrorrhagia.

The physical examination is non-specific, and most often reveals a pelvic mass, an enlarged uterus.<sup>[16,17]</sup> with on speculum examination, a cervical or endometrial polyp (22%) delivered through the cervix, which may be considered as the origin of the bleeding and confused with the tumor.<sup>[5,8,14,15]</sup> as was the case for our patient. Thus, biopsy of a polyp delivered through the cervix, or biopsy curettage of the endometrium, are not always sufficient to make the diagnosis. It is only after the anatomopathological study of the hysterectomy specimen that the diagnosis is affirmed, revealing the two malignant mesenchymal and benign epithelial contingents.<sup>[18]</sup>

The histological diagnosis is accurate in only 25% of cases,<sup>[5,8]</sup> hence, many differential diagnoses can be considered, namely: low-grade endometrial stromal tumors, carcinosarcomas, adenofibromas, and embryonal rhabdomyosarcoma, especially in small specimens. The distinction between these different histological entities is best appreciated by applying morphological criteria. Immunohistochemistry has a limited role.<sup>[19]</sup>

The optimal treatment for adenosarcoma is surgery, consisting of hysterectomy, usually with bilateral salpingo-oophorectomy,<sup>[8,20,21]</sup> because it is usually a low-grade malignant tumor,<sup>[22]</sup> with essentially local development, rarely invading the myometrium.<sup>[23]</sup> Pelvic lymphadenectomy remains controversial. According to the literature, the invasion of the myometrium, the enlarged proliferation of the tumor, and the lymph node involvement expose the patient to locoregional recurrence, and to peritoneal and pulmonary metastases, which appear within 5 years in 30% of cases.<sup>[24]</sup> Our patient underwent a total hysterectomy with bilateral adnexectomy and pelvic curage due to the invasion of more than 50% of the myometrium on imaging.

Regarding the contribution of adjuvant treatment (chemotherapy and radiotherapy) in this type of tumor, the data are very controversial, due to the lack of studies and follow-up.<sup>[17]</sup> The latter is not well defined. Adjuvant radiotherapy seems to have a role in better pelvic control and in reducing local tumor recurrence.<sup>[25]</sup> On the other hand, adjuvant chemotherapy in patients with advanced disease or risk factors for recurrence may lead to prolonged progression-free survival.<sup>[5,21,23]</sup>

Adenosarcoma is rarely metastatic,<sup>[14]</sup> however, local recurrence is common and can occur in up to 50% of cases.<sup>[21]</sup> Recurrence and metastasis depend on myometrial invasion.<sup>[1]</sup> Our patient is currently 3 years after her surgical treatment, without recurrence.

## CONCLUSION

Adenosarcoma is an uncommon neoplasm of the female reproductive tract, occurring most commonly in the uterus. The prognosis is significantly worsened by the presence of myometrial invasion and/or sarcomatous proliferation.

The standard treatment is surgical consisting of total hysterectomy and bilateral adnexectomy. Spread to regional lymph nodes is rare, hence lymphadenectomy is not necessary unless there is clinical suspicion before resection. The role of chemotherapy in the adjuvant setting requires further investigation. Additional research is needed to help improve patient outcomes with this rare disease.

## Conflict of interest

I declare that I have no conflict of interest.

## REFERENCES

1. Clément PB, Scully RE. Mullerian adenosarcoma of the uterus. A clinicopathologic analysis of ten cases of a distinctive type of mullerian mixed tumor. *Cancer*, 1974; 34: 1138-1149.
2. Uwe A. Ulrich a Dominik Denschlag b. Uterine Adenosarcoma Review Article *Oncol Res Treat*, 2018; 41: 693–696.
3. Valette H, Milleret P. Adénosarcome müllérien de l'utérus : revue de la littérature à propos d'un cas. *Rev Fr Gynecol Obstet*, 1988; 83: 193-5.
4. Michael J. Nathenson<sup>1</sup> & Vinod Ravi<sup>2</sup> & Nicole Fleming<sup>3</sup> & Wei-Lien Wang<sup>4</sup> & Anthony Conley<sup>2</sup>. Uterine Adenosarcoma: a Review. Springer Science+Business Media New York, 2016.
5. Kabwa L, Mattei JP, Eloït S, Ramadane A, Grange B. Un cas d'adénosarcome utérin et vaginal dans un contexte de prolapsus génital remanié. *J Chir*, 1997; 134: 80-5.
6. Piura B, Rabinovich A, Meirovitz M, Yanai-Inbar I. Mullerian adenosarcoma of the uterus: case report and review of literature. *Eur J Gynaecol Oncol* 2000; 21: 387-90.
7. Clement PB. Mullerian adenosarcomas of the uterus with sarcoma-tous overgrowth. A clinicopathological analysis of 10 cases. *AmJ Surg Pathol*, 1989; 13: 28–38.
8. Clement PB, Scully RE. Mullerian adenosarcoma of the uterus: a clinicopathologic analysis of 100 cases with a review of the literature. *Hum Pathol*, 1990; 21: 363–381.
9. Kaku T, Silverberg SG, Major FJ, et al. Adenosarcoma of the uterus: a Gynecologic Oncology Group clinicopathologic study of 31 cases. *Int J Gynecol Pathol*, 1992; 11: 75–88.
10. Zaloudek CJ, Norris HJ. Adenofibroma and adenosarcoma of the uterus: a clinicopathologic study of 35 cases. *Cancer*, 1981; 48: 354–366.
11. H Farhat M., Hobeika E.M., Moumneh G., Nassar A.H. Uterine mullerian adenosarcoma with sarcomatous overgrowth fatal recurrence within two weeks of diagnosis: a case report. *Journal of Medical Case Reports*, 2007; 1: 103.
12. Tjalma WA, Michener CM: Mullerian adenosarcoma of the uterus associated with long-term oral contraceptive use. *Eur J Obstet Gynecol Reprod Biol*, 2005; 119: 253-4.
13. Wysowski DK, Honig SF, Beitz J: Uterine sarcoma associated with tamoxifen use. *N Engl J Med*, 2002; 346: 1832-3.
14. Valette H, Milleret P. Adénosarcome müllérien de l'utérus : revue de la littérature à propos d'un cas. *Rev Fr Gynecol Obs-tet*, 1988; 83: 193-5.
15. Bobin JY, Jaquot F, Lafont A, Rivoire M, Shisheboran M, Dolbeau D. L'adénosarcome utérin : revue de la littérature à propos d'un cas. *J Gynecol Obstet Biol Reprod*, 1993; 22: 245-8.
16. PHILIP B. CLEMENT, MD, AND ROBERT E. SCULLY, MD HUMAN PATHOLOGY. Mullerian Adenosarcoma of the Uterus:A Clinicopathologic Analysis of 100 Cases with a Review of the Literature, 1990; 21(4).
17. Mirna H Farhat\*1, Elie M Hobeika2, Ghada Moumneh3 and Anwar H Nassar2. Uterine mullerian adenosarcoma with sarcomatous overgrowth fatal recurrence within two weeks of diagnosis: a case report. *Journal of Medical Case Reports*, 2007; 1: 103. doi:10.1186/1752-1947-1-103.
18. R. Fatnassi, F. Amri. L'adénosarcome utérin à propos d'un cas. *Gynecol Obstet Biol Reprod*, 2005; 34(cahier 1): 270-272.
19. Robert A. Soslow, MD,\* Asya Ali, MD,\* and Esther Oliva, MDw. Mullerian Adenosarcomas: An Immunophenotypic Analysis of 35 Cases.
20. Pautier P. Sarcomes utérins. *Oncologie*, 2007; 9: 137-143.
21. Bernard JL, Leon B. Tumeurs rares de l'utérus. *Gynécologie*. Ed Pradel, 1993; 433-436.
22. Bobin JY and al. L'adénosarcome utérin : revue de la littérature à propos d'un cas. *J Gynecol Obstet Biol Reprod*, 1993; 22: 245-248.
23. Del Carmen MG, Lovett D, Goodman A. A case of mullerian adenosarcoma of the uterus treated with liposomal doxorubicin. *Gynecol Oncol*, 2003; 88: 456-8.
24. Z. Benzarti1, I. Zemni1, M. Ghalleb1, T. Damak1, M. Driss2, M. Hechiche1, and K. Rahal. Adénosarcome utérin: étude de 5 cas [Adenosarcoma of the Uterus: a clinicopathologic analysis of 5 cases]. *International Journal of Innovation and Scientific Research ISSN 2351-8014*, Aug. 2016; 26(1): 255-259.
25. Hornback NB, Omura G, Major FJ: Observations on the use of adjuvant radiation therapy in patients with stage I and II uterine sarcoma. *Int J Radiat Oncol Biol Phys*, 1986; 12: 2127-30.