

ANALYSIS OF APPENDECTOMY OUTCOMES AND CORRELATION OF ITS DIAGNOSTIC FEATURES AND INTRA-OPERATIVE FINDINGS

Dr. Weam Rashad Ismail*

M. B.Ch. B. High Diploma General Surgery - College of Medicine /Baghdad University, High Diploma General Surgery Department: surgery – Al-Shahid Al-Sadr Hospital.

Corresponding Author: Dr. Weam Rashad Ismail

M. B.Ch. B. High Diploma General Surgery - College of Medicine /Baghdad University, High Diploma General Surgery Department: surgery – Al-Shahid Al-Sadr Hospital.

Article Received on 27/01/2021

Article Revised on 17/02/2021

Article Accepted on 07/03/2021

ABSTRACT

Appendicitis is the most common surgical disease with appendectomy being the traditional treatment of choice. Different operative procedures exist for appendectomy. This retrospective study aimed to correlate the different diagnostic features of acute appendicitis (AA), and correlate different intra-operative findings during appendectomy and to analyze the operative outcome in the follow-up period. The current study was done during the period from January 2019 to June 2020 in the Department of surgery, Al-Shahid Al-Sadr Hospital-Baghdad/Iraq on 150 operative patients who were analyzed with AA as diagnosis. Choice of appendectomy, whether laparoscopic or open, was based on clinical judgment of operating surgeon. Results showed that out of 150 patients, 110 and 40 were operated via open and laparoscopic approach respectively. The most common symptom was pain in right iliac fossa (96.7%), 16.7% had perforation, while 27.3% had inflamed appendix. Histopathological assessment showed that 9.3% and 2.7% had suppurative and gangrenous appendicitis respectively. In addition, 20.0% of the open cases were reported with Surgical Site Infection (SSI). No SSI was reported in the laparoscopic group. Post-operative duration for open and laparoscopic appendectomy was 5.3 ± 1.1 and 3.5 ± 1.2 minutes ($P = 0.479$) and was not found to be statistically significant. It can be concluded from our study that open appendectomy is considered safe and effective but associated with complications such as ileus, intestinal obstruction, wound sepsis etc. Laparoscopic appendectomy with high accuracy and low complication rate has emerged as the modus operandi for treatment of AA.

KEYWORDS: Appendectomy; Acute appendicitis; Surgical site infection; CT scan.

INTRODUCTION

Appendicitis is the most common surgical disease with appendectomy being the traditional treatment of choice. The diagnosis of Acute Appendicitis (AA) was based on clinical signs and symptoms before the advent of widespread use of sonography and CT scans. Several diagnostic scoring systems such as Alvarado score, (AIR) Appendicitis Inflammatory Response (Andersson score), World Society of Emergency Surgery (WSES), AA grading system have been described.^[1] Obstruction of the lumen of appendix triggers a series of events that leads to AA. Fecalith is the most common cause of obstruction, others being lymphoid hyperplasia, edema, stricture, gallstones, adhesions etc.^[2] Emergency appendectomy was the choice of treatment for AA initially and any sort of delay in operative intervention was believed to lead to complications like perforation, periappendiceal abscess etc. However, studies have shown that delayed appendectomy though less superior, does not lead to increased morbidity.^[3]

Different operative procedures exist for appendectomy such as open appendectomy, laparoscopic appendectomy, Single Incision Laparoscopic Surgery (SILS)/Single Port Laparoscopy (SPL) and via transvaginal route (NOTES; Natural Orifice Transluminal Endoscopic Surgery). The idea of minimal access surgery has made laparoscopy a far more attractive option than the open approach. However, many studies have shown conflicting results. Some have demonstrated that laparoscopic route has better clinical outcomes while other has shown marginal or no clinical benefits and higher costs. Thus, there is no single consensus regarding the superiority of laparoscopic route over open.^[4] However, there is a growing trend towards minimal access surgery (laparoscopy) due to the reduced magnitude of surgical injury and enhanced rate of patient's return to homeostasis and recovery.

Open appendectomy is considered safe and effective but associated with complications such as ileus, intestinal obstruction, wound sepsis etc. Laparoscopic

appendectomy with high accuracy and low complication rate has emerged as the modus operandi for both diagnosis and treatment of AA.^[5]

MATERIALS AND METHODS

The present retrospective study was done between January 2019 and January 2020 in the Department of surgery–Al-Shahid Al-Sadr Hospital on 150 patients who were analyzed with AA as diagnosis. All patients who were operated for appendectomy, whether laparoscopic or open were enrolled in the study. Record was obtained from online patient data entry and from offline individual case files.

Demographic data such as age and sex along with clinical features and investigative findings were all collected and compiled. Data regarding patient follow-up for post-operation complications like wound sepsis, intra-abdominal abscess, ileus, intestinal obstruction etc were collected from online record entry. The following diagnostic criteria was used: Migratory Right Iliac Fossa (RIF) pain, anorexia, nausea and vomiting, RIF tenderness, rebound tenderness, elevated temperature, leucocytosis, shift to left.

All routine lab. investigations were done along with sonography. Choice of appendectomy, whether laparoscopic or open, was based on clinical judgment of operating surgeon. All samples were sent for histopathological reporting. Final diagnosis was made with the help of intra-operative findings and histopathological reports.

Statistical analysis

Data were analyzed using SPSS v20. Continuous variables were presented as mean \pm SD, and categorical

variables were presented as absolute numbers and percentages. The comparison of normally distributed continuous variables between the groups was performed using Student's t-test. Nominal categorical data between the groups were compared using Chi-square test. For all statistical tests, a p-value less than 0.05 was considered as significant.

RESULTS

A total of 150 patients were operated for appendectomy out of which 110 (73.3%) were via open approach and 40 (26.7%) were via laparoscopy. In the open appendectomy group, 71 (64.5%) were males and 39 (35.5%) were females, whereas in laparoscopic appendectomy, males and females were 26 (65.0%) and 14 (35.0%) respectively with no significant variations ($P>0.05$). The average age for males and females in open appendectomy was 29.5 ± 10.2 (Mean \pm SD) and 31.5 ± 11.4 respectively. In laparoscopic, the average age for males and females was found to be 29.5 ± 12.7 and 31.3 ± 10.7 respectively with no significant differences ($P>0.05$).

Most common symptom for appendicitis was found to be abdominal pain in right iliac fossa 145 (96.7%), followed by nausea and vomiting 83 (55.3%). Fever was present in 27 (18.0%) patients. The most common sign was tenderness in right iliac fossa 84 (56.0%) followed by rebound tenderness 41 (27.3%). Among the laboratory parameters, leucocytosis was found in 38 (25.3%) followed by shift to left 23 (15.3%) (Figure 1). From an intra-operative point of view, 25 (16.7%) patients had a perforated appendix, 41 (27.3%) had mild to moderately inflamed appendix, 13 (8.7%) had retro-cecal appendix, 4 (2.7%) were gangrenous and only 3 (2.0%) had mucocele appendix (Figure 2).

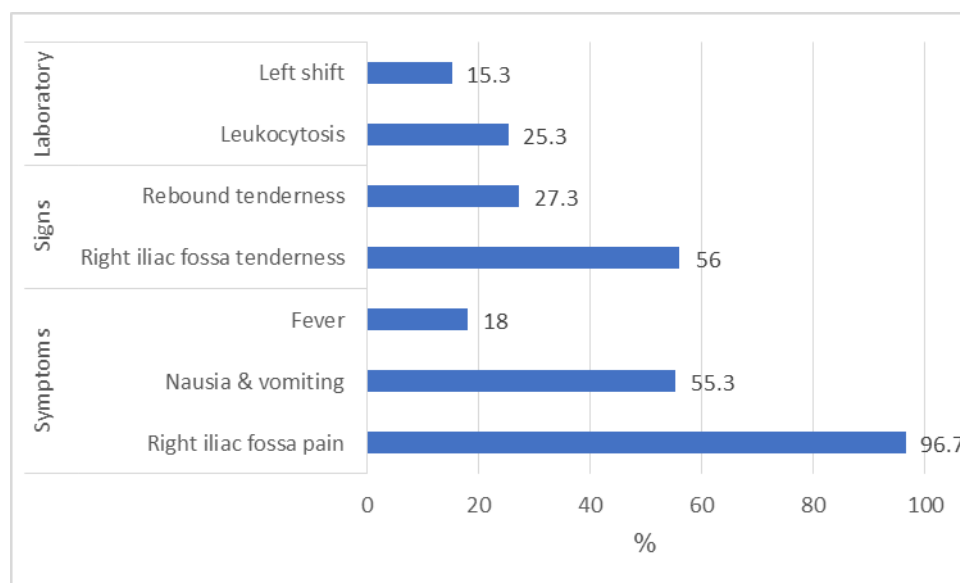


Figure (1): Preoperative signs, symptoms and laboratory most common findings.

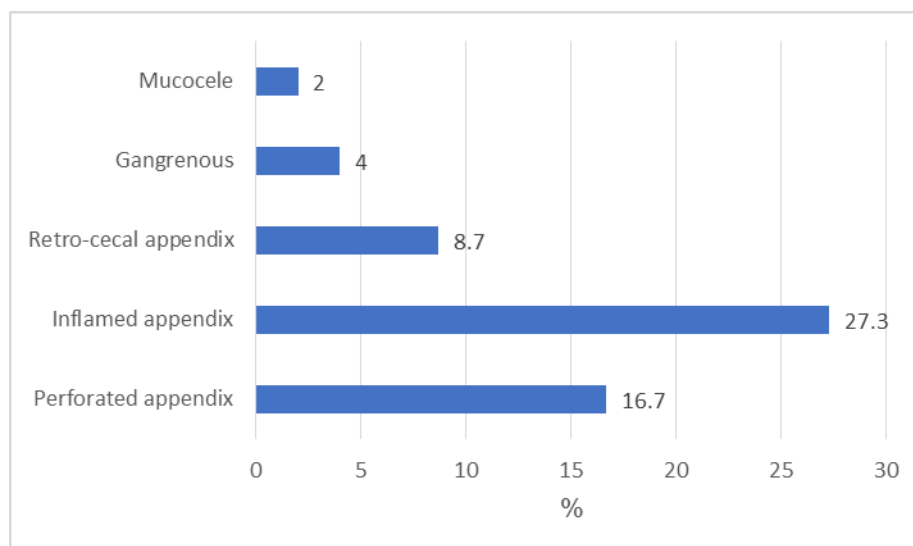


Figure (2): Post operative findings.

Histopathological assessment of all the appendix specimens showed that 42 (28.0%) had acute appendicitis, 26 (17.3%) had chronic appendicitis, 31 (20.6%) had acute or chronic appendicitis, 14 (9.3%) had suppurative appendicitis and 4 (2.7%) had gangrenous appendicitis.

Also, 61(55.5%) out of 110 patients who underwent open appendectomy had post-operative complications. 25 (20.0%) of the OA cases reported with surgical site infection (SSI) in the form of wound gape in the follow-up period which was then treated with either re-suturing

or healing by secondary intention with regular cleaning and dressing.

Among patients who underwent open appendectomy, post-op ileus was encountered in 8 (7.3%) and faecal fistula was reported in only 1 (0.9%) patient. No post-op complication was reported in the laparoscopic group. Post-op duration for open and laparoscopic appendectomy was 5.3 ± 1.1 and 3.5 ± 1.2 ($P = 0.479$) which was not found to be statistically significant as shown in table (1).

Table (1): Histopathology, post operative complications and post operative duration.

| | Findings | Count | % |
|--|-------------------------------|-------|------|
| Histopathology | Acute appendicitis | 42 | 28.0 |
| | Chronic appendicitis | 26 | 17.3 |
| | Acute or chronic appendicitis | 31 | 20.6 |
| | Suppurative appendicitis | 14 | 9.1 |
| | Gangrenous appendicitis | 4 | 2.7 |
| Post operative complications | Open appendectomy | 110 | 55.5 |
| | SSI | 22 | 20.0 |
| | Post operative ileus | 8 | 7.3 |
| | Faecal fistula | 1 | 0.9 |
| | Laparoscopic group | 0 | 0 |
| | | Mean | SD |
| Post operative duration (minutes) | Open appendectomy | 5.3 | 1.1 |
| | Laparoscopic group | 3.5 | 1.2 |

DISCUSSION

A retrospective study conducted by Ioannis and Constantinos,^[9] in 2018 showed that although OA is easy and fast, LA becomes more minimal with the one port technique and operative time also reduces after training. LA was recommended as a routine surgical technique. Although operative time was not an evaluated parameter in our current study, it can be concluded that laparoscopic approach fares better than open appendectomy based on other studied factors. Other

studies showed similar results like Dr. Ekka,^[6] who studied the clinical presentation of 125 patients for a period of 2 years. Alvarado scoring in the evaluation of acute appendicitis was studied by Özsoy et al.^[7] and by Mahesh et al.^[8]

Retrospective data from 593 patients was collected by Biondi et al.^[10] in 2016 and was compared for operative time, length of hospital stay, postoperative pain, complication rate, return to normal activity and cost. It

was found that in LA, hospital stay was shorter (2.7 ± 2.5) days with faster return to normal activity (11.5 ± 3.1) days, although total operative time for LA was more (31.36 ± 11.13 min. in OA and 54.9 ± 14.2 in LA). Incidence for intra-abdominal abscess was found to be more in LA but it could be reduced with training and experience. Both procedures are still in practice with surgeon's choice being the decisive factor. No intra-abdominal abscess was reported in our study. However, other post-op complications were present after open appendectomy like Surgical Site Infections (SSI), ileus, fecal fistula etc., whereas none were reported after laparoscopic approach.

Khatana et al.^[11] conducted a similar study in 2018. The study concluded that although post-op pain was more in OA, nausea was more pronounced in the laparoscopic group. No significant difference was found in the rest of the post-op complications. Even post-op stay duration was found to be statistically insignificant. Thus, the results of LA were comparable to OA, if not better. In our study, laparoscopic approach was reserved only for elective cases while all the emergency appendicitis cases were treated with open appendectomy. Cases posted electively that had significant guarding and rigidity and had been given a trial of antibiotics were also treated by open appendectomy.

A prospective study was conducted in 2015 among 187 patients. No significant difference was found with regard to hospital stay, post-op analgesia; return of bowel sounds and to daily activity. Cost of LA was more than OA. It was concluded that appendectomy in acute uncomplicated appendicitis was a safe procedure, regardless of the technique involved.^[12] Post-op recovery was found to be better after LA in our study while being a government sector, cost was almost equal for both the procedures.

Shimoda et al.^[13] conducted a study in 2017 with statistically significant difference found in duration till resuming oral intake, blood loss and surgical site infection. Although operating time is longer with LA, it can be reduced with proper training and further experience. Operating time not only depends upon surgeon experience but also upon the complications that might occur during the procedure. Thus, it is difficult to have a uniform comparison between operative times of two different techniques as it is impossible for every intra-operative encounter to be similar.

Moreover, 763 appendectomies were conducted and studied between 2007- 2012 and analyzed by Islam et al.^[14] Conversion of lap to open was found in 11 cases (3.4%). Concomitant pathologies were encountered and subsequently managed including 10 cholecystectomies, 4 tubal pregnancies and 6 ovarian cystectomies. No such events were encountered in the present study.

The 70 patients were analyzed for pre-op, intra-op and post-op parameters during 2013 to 2014 by Subramaniam.^[15] Operative time and total blood loss was slightly more in OA as compared to LA. Early discharge from hospital was found in LA cases. Zero mortality was found in all the cases. LA was safe and feasible in complicated appendicitis.

Shrivastava et al.^[16] studied 80 patients in 2019. Intraoperatively, retrocecal appendix was found in 51 cases. Operative time was more in LA and significant difference was found in post-op complications. In 47.5% OA and 25% LA cases had post-op complications. Wound infection was seen in 25% OA and 13.9% LA cases. However, according to other studies there was no significant advantage of LA over OA except quality of life at 2 weeks. LA also took longer to perform. Thus, the decision between whether to perform OA or LA depended upon the surgeon or patient or both.^[17,20]

In 2018, Patel et al.^[21] conducted a study on 88 patients (65 OA and 23 LA). Mean age was found to be 27.83 and 27.28 years respectively. In 4 were interval and 19 were emergency appendectomies which were performed on patients with recurrent symptoms. Out of all the OA cases, 27 were acute appendicitis, 20 were recurrent appendicitis and remaining 18 were interval appendectomies. In the present study, 28.0% had acute appendicitis, 17.3% had chronic appendicitis, 20.6% had acute or chronic appendicitis, 9.1% had suppurative appendicitis and 2.7% had gangrenous appendicitis.

Goudar et al.^[22] conducted a study in Southern India among 240 patients. Post-op pain was stratified into mild, moderate and severe and was found to be less in LA. In a study done by Mukherjee et al.^[23] in a rural district setup in India statistical significance with p-value < 0.0001 was found comparative entities such as mean incision length in cm, mean duration of surgery in minutes, mean parenteral analgesic doses, mean oral analgesic doses, time to start oral feeding in hours, time to ambulation, post-op pain after 24 h, hospital stay in days, patient acceptance likert scale and non-significance was found in intra-op and post-op complications. Mehta studied 50 consecutive cases in a rural population. They reported that all the patients presented with complaint of abdominal pain, 64% amongst OA and 80% amongst LA presented with nausea/vomiting. 28% OA and 20% LA cases complained of fever at the time of admission. All the patients showed tenderness on palpation while guarding/ rigidity was present in 24% OA and 16% LA cases. 80% and 72% of OA and LA patients showed differential count with shift to left.^[24] Similarly in our study, RIF pain and tenderness featured prominently amongst patient's chief complaints whereas shift to left was seen in 15.3%.

The 100 appendicitis patients were studied by Mehta et al. during 2016 to 2017 out of which 55% LA and 60% OA cases had inflamed appendix, 25% LA and 20% OA

had adhesions, 2.5% LA and 5% OA had appendicular lump, 12.5% LA and 6.76% had OA had distended appendix, 10% LA and 8.3% OA had appendicular perforation while the rest were normal.^[25]

Post-op complications were studied by Kumar and Rao,^[26] in 200 cases. 20% and 10% OA and LA cases respectively had vomiting. Abdominal abscess was found to be a complication in 5% OA cases while no such complication had occurred in LA cases. Wound infection occurred in 17% open and 4% of laparoscopic cases. Ileus was found in both but was less in laparoscopic group. The 820 appendectomies were analyzed over a period of 5 years by Senapati et al.^[27] In the laparoscopic group, injury to inferior epigastric artery due to trocar occurred in 2 cases while in 13 cases, the approach became difficult due to dense adhesion and was subsequently converted to open. The 21 cases reported with surgical site infection among the open group. The 6 cases reported with surgical site hernia among open cases and 2 laparoscopic cases presented with umbilical port hernia.

REFERENCES

- Sartelli M, Baiocchi GL, Saverio S Di, Ferrara F, Labricciosa FM, Ansaloni L, et al. Prospective Observational Study on acute Appendicitis Worldwide (POSAW). *World J Emerg Surg*, 2018; 13: 19.
- Kotwal SR, Jadav JS. Retrospective study of single dose of antibiotic in laparoscopic appendectomy. *Int Surg J.*, 2018; 5(5): 1897.
- Shin CS, Roh YN, Kim JI. Delayed appendectomy versus early appendectomy in the treatment of acute appendicitis: A retrospective study. *World J Emerg Surg*, 2014; 9(1): 8.
- Kehagias I, Karamanacos SN, Panagiotopoulos S, Panagopoulos K, Kalfarentzos F. Laparoscopic versus open appendectomy: Which way to go ? *World J Gastroenterol*, 2008; 14(31): 4909-14.
- Islam SR, Pasha K, Rahman S, Nasir E, Hanif E, Barman A. Laparoscopic vs. Open Appendectomy: A Comparative Study. *Bangladesh J Endosurgery*, 2014; 2(1): 5-8.
- Ekka NMP. A Clinicopathological Study of Acute Appendicitis in Eastern India. *Int J Med Dent Sci.*, 2016; 5(2): 1145.
- Özsoy Z, Yenidoğan E. Evaluation of the Alvarado scoring system in the management of acute appendicitis. *Turk J Surg*, 2017; 33(3): 200-4.
- Mahesh SV, Hota PK, Sneha P. A study of Alvarado score and its correlation with acute appendicitis. *Int Surg J.*, 2017; 3(4): 2.
- Ioannis V, Constantinos F. Comparison between Open and Laparoscopic Appendectomy: A Systematic Review. *World J Surg Surgical Res.*, 2018; 1: 1004.
- Biondi A, Di Stefano C, Ferrara F, Bellia A, Vacante M, Piazza L. Laparoscopic versus open appendectomy: A retrospective cohort study assessing outcomes and cost-effectiveness. *World J Emerg Surg*, 2016; 11(1): 44.
- Khatana PS, Kumar J, Aggarwal M. Comparison of open versus laparoscopic appendectomy. *Int Surg J.*, 2018; 6(6): 2133-7.
- Karatparambil A, Kummarkandath SA, Mannarakkal R, Nalakath MR, Babu D. Laparoscopic versus open appendectomy: A comparative study. *Int Surg J.*, 2016; 3(1): 128-34.
- Shimoda M, Maruyama T, Nishida K, Suzuki K, Tago T, Shimazaki J, et al. Comparison of clinical outcome of laparoscopic versus open appendectomy, single center experience. *Heliyon*, 2018; 4(5): e00635.
- Islam SR, Pasha K, Rahman S, Nasir E, Hanif E, Barman A. Laparoscopic vs. Open Appendectomy: A Comparative Study. *Bangladesh J Endosurgery*, 2014; 2(1): 5-8.
- Subramaniam RK. Comparative analysis of clinical outcomes of open appendectomy and laparoscopic appendectomy. *Int J Contemp Med Res*, 2018; 5(1): 18-20.
- Shrivastava A, Jain A, Jain R. Laparoscopic versus conventional open appendectomy: A prospective comparative analytical study in a tertiary care set up. *Int Surg J.*, 2019; 7(7): 2536-41.
- Katkhouda N, Mason RJ, Towfigh S, Gevorgyan A, Essani R. Laparoscopic versus open appendectomy. *Ann Surg*. 2005; 242(3): 439-50.
- Pradhan S, Shakya YR, Batajoo H, Malla B, Joshi HN, Thapa LB, et al. Laparoscopic versus open appendectomy: A prospective comparative study. *J Soc Surg Nepal*, 2015; 18(2): 29-32.
- Liu Y, Cui Z, Zhang R. Laparoscopic versus open appendectomy for acute appendicitis in children. *Indian Pediatr*, 2017; 54(11): 938-41.
- Wang CC, Tu CC, Wang PC, Lin HC, Wei PL. Outcome comparison between laparoscopic and open appendectomy: Evidence from a nationwide population- based study. *PLoS One*, 2013; 8(7): e68662.
- Patel VK, Sharma S, Gaharwar APS, Gupta R. A comparative study between laparoscopic appendectomy and conventional open appendectomy. *IJSS J Surg*, 2018; 4(2): 20-5.
- Goudar BV, Telkar S, Lamani YP, Shirbur SN, Shailesh ME. Laparoscopic versus open appendectomy: A comparison of primary outcome studies from southern India, 2011; 5(8): 1606-9.
- Mukherjee R, Samanta S, Sinha A, Alam RA, Samanta PC, Halder T, et al. A comparative study of laparoscopic versus open appendectomy in a district hospital setup, 2018; 6(11): 840-5.
- Kumar GS, Rao DN. Open versus laparoscopic appendectomy: A comparative study. *Int J Surg Sci.*, 2018; 2(2): 19-22.
- Singh LM, Wadiwa YS. A retrospective comparative study between laparoscopic and open appendectomy in teaching hospital of India. *Int Surg J.*, 2018; 5(9): 3034-7.

26. Kumar GS, Rao DN. Open vs laparoscopic appendicectomy: A comparative study, 2018; 2(2): 19-22.
27. Senapati JN, Dash A, Hansa J. Evolvement of laparoscopic appendicectomy in a tertiary care teaching hospital. Bull Env Pharmacol Life Sci., 2016; 5(10): 35-9.