

TOBACCO RELATED LESIONS OF THE ORAL CAVITY

¹Dr. Manju J, M. D. S., ²Dr. C. Krithika, M. D. S, Ph.D., ³*Dr. K. Ovia Irish Kumari, B.D.S.

¹Senior Lecturer Thai Moogambigai Dental College and Hospital Dr. M.G.R Educational and Research Institute University.

²Professor & Head Thai Moogambigai Dental College and Hospital Dr. M.G.R Educational and Research Institute University.

³C.R.R.I. Thai Moogambigai Dental College and Hospital Dr. M.G.R Educational and Research Institute University.

*Corresponding Author: Dr. K. Ovia Irish Kumari, B.D.S.

C.R.R.I. Thai Moogambigai Dental College and Hospital Dr. M.G.R Educational and Research Institute University.

Article Received on 27/06/2019

Article Revised on 17/07/2019

Article Accepted on 07/08/2019

ABSTRACT

Tobacco smoking poses a risk to health due to the inhalation of poisonous chemicals in tobacco smoke which starts with causes of oral cavity. The appearance of the lesion is variable depending upon the type of tobacco used, and the frequency and duration of use, generally refers to a firmly attached white patch on a mucosa which is associated with an increased risk of cancer. The condition is remotely linked to oral cancers and is associated with areca nut or betel quid chewing, a habit similar to tobacco chewing. Chewing tobacco is causes dreadful condition it is not substitute for smoking cigarettes. Nicotine content in chewing tobacco is vastly addictive has a numerous amount of carcinogenic agents. Any form of tobacco use poses an increased risk of developing cancer, and no level is considered safe, People who stop smoking greatly reduce their risk for disease and early death, to overcome addiction of counselling, drugs are prescribed.

KEYWORDS: Tobacco, smoking, smokeless lesion, cessation, potentially malignant lesion.

INTRODUCTION

Tobacco is dangerous to health which damages the oral cavity; presence of lesion in the cavity reveals systemic abnormality.^[1] A Precancerous Lesion is a morphologically altered tissue in which oral cancer is more likely to occur than in its apparently normal counterpart (WHO). A Precancerous Condition is a generalized state associated with a significantly increased risk of cancer (WHO).^[2] Lesion with tobacco and betel chewing habits has been recorded more commonly in Asia by association of oral precancerous lesions.^[3] Tobacco utilization occurs mainly in developing countries with low levels of education, mostly among men which causes deadly diseases like oral cancer, leukoplakia.^[4] Tobacco habits are in form of smoked and chewed forms substances are nicotine, irritants, toxins, carcinogens.^[5] Consumption of tobacco leads to periodontal diseases, bone loss, affects clinical procedures annually cigarettes usage exceeds to 5.8 trillion through the world.^[6] Tobacco use in excessive manner leads to various lesion in the oral cavity, affects minor salivary glands in hard palate, gingival recession, clinical attachment loss.^[7] Soft tissue lesions of higher level assign host modification and genetic factors due to provoking effects in the mucosa.^[8] Evidence of active and passive consumption leads to risk of oral cancer at

the condition of more than one pack per day.^[9] Smoking patterns are daily smoking (everyday), occasional smoking (smokes but not every day).^[10] Common malignancies are Squamous cell carcinoma (SCC) at the site of tongue floor the mouth, lip, and gingival, Verrucous carcinoma at the site of buccal mucosa, gingiva, alveolar ridge.^[8]

Classification: TOBACCO forms are

1. Smoke
2. Smokeless

Smoke: Cigar, Beedi, Hookah, Reverse smoke.
Smokeless: Paan, Paan Masala, Mawa, Khaini.^[5]

Precancerous Lesion Condition

1. Leukoplakia 1.Submucous Fibrosis
2. Erythroplakia 2.Actinic Keratosis
3. Smokers Palate 3.Lichen Planus
4. Reverse Smoking 4.Discoid Lupus

Erythromatosis.^[7]

Waranakulasuriya Classification.^[8]

1. Homogeneous
2. Non homogeneous

- Verrucous
- Papillary (nodular)
- Speckled.

Tobacco Related Lesion.^[5]

- Tobacco pouch keratosis
- Preleukoplakia
- Leukoedema
- Paan stain and encrustation
- Lichenoid reaction
- Excrescence
- Tobacco lime user lesion
- Patches
- Red areas
- Ulcerated areas
- Hyper pigmentation areas
- Non pigmented areas
- Oral cancer
- Hereditary disorder with increased risk.

Other Tobacco Related Lesion.^[11,12]

Common oral mucosa lesions

- Central papillary atrophy of the tongue
- Palatal erythema with papillary hyperplasia
- Periodontal diseases
- Localized gingival recession
- Increased caries
- Halitosis
- Discolouration of teeth
- Excessive wear on the teeth due to abrasion

Sign and Symptoms

- Sore\ tenderness of mouth
- Pain
- Tenderness\ numbness in mouth\ lip
- Lump\ leathery patch inside mouth\ colour\ Change of tissue intraorally Patch – GREY, RED, WHITE
- Difficulty in chewing, swallowing \ speaking.
- Often history of mucosa trauma.
- Ear pain
- Weight loss
- Flu like symptoms
- Trauma - Dental caries
- Incorrectly\ Irregularly covered bone
- Improper prosthesis.^[13,14]

Etiology

1. Human papilloma virus (HPV)
2. Betel quid.
3. Alcoholism.
4. Smoking- pipe, cigarette\ cigar.
5. Smokeless- chewing tobacco, snuff.
6. Chronic friction.
7. Ingestion of chillies.
8. Immunogenic antigens (HLA).
9. Hereditary \ congenital.^[15,6]

Leukoplakia

Leukoplakia is most common precancerous lesion which occurs on the tongue, buccal mucosa, white patches, on

the oral cavity it persist, recur leads to cancer.^[6] A white patch or plaque that cannot be characterized clinically or pathologically as any other disease (WHO).^[2] Malignant transformation shows greater in smokers than non smokers.^[16] Oral leukoplakia is asymptomatic, pain occurs\ itching may occur arise slowly for several months\ years.^[17]

Phases of Leukoplakia

- Thin grey white translucent which is soft and flat
- Homogeneous thick smooth \ fissured
- Nodular \ granular surface \ verruciform
- Erythroplakia, speckled, non homogeneous.^[6]

Clinically

- Homogeneous
 - common in buccal mucosa white plaque have low premalignant
- Non Homogeneous
 - Speckled whitish flecks high risk of malignant.^[6,19]

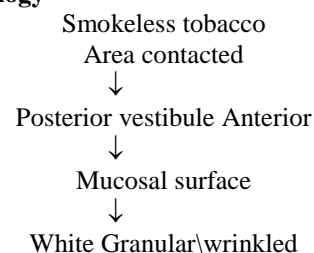
Staging

- L1 - size < 2 cm
- L2 - size 2- 4 cm
- L3 - size > 4 cm
- Lx - size not specified
- P - pathology
- PO – no epithelial dysplasia
- PI - distinct epithelial dysplasia
- PX – not specified.^[1]

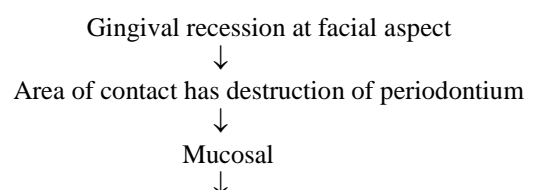
Stage System

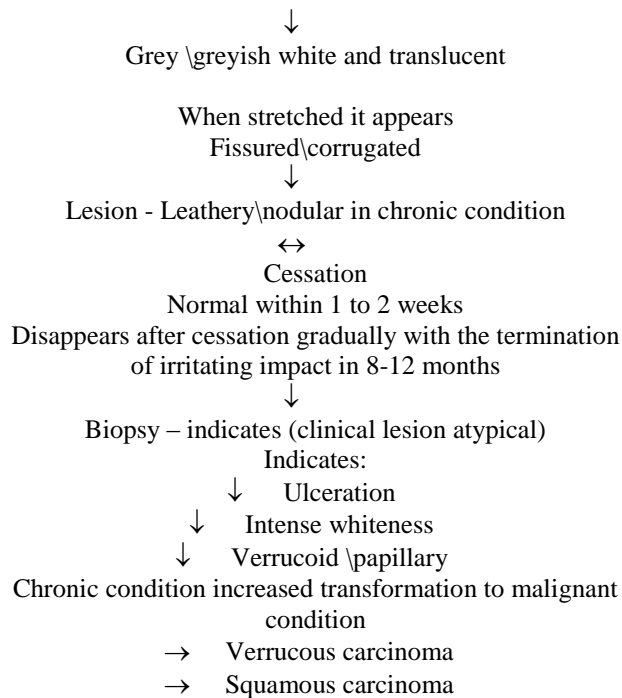
Stage I - L1 PO
 Stage II - L2 PO
 Stage III - L3 PO\ L1L2PI
 Stage IV – L3 P1.^[1]

Pathophysiology



- ↙ Flat white patch\ plaque without red components
- ↙ white patches with erosion
- ↙ Slightly elevated
- ↙ Marked raised \ elevated patch





Leukoplakia → 1.36 per year.^[5,6]

Differential diagnosis

- White sponge nevus
- Frictional keratosis
- Leukoedema
- Lichen planus\lichenoid reaction
- Hairy leukoplakia
- Leukokeratosis nicotina palate.^[5,18]

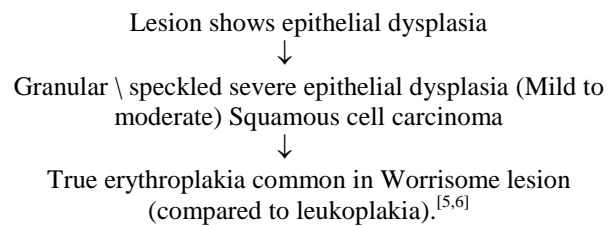
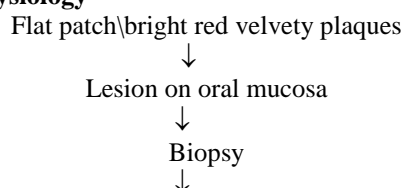
Erythroplakia

Erythroplakic lesions of the oral mucosa which is bright red velvety plaques cannot be characterized clinically \ pathologically recognizable like any other condition.^[7] Erythroplakia shows epithelial dysplasia, flat red patch with tobacco is premalignant lesions greater risk of cancer.^[1] A fiery red patch that cannot be characterized clinically\pathologically as any other lesion.^[20] Erythroplakia has high risk in malignant transformation.^[21] Tobacco and alcohol is the main, factor which causes erythroplakia.^[22] Common site of lesion are soft palate, floor of the mouth, ventral surface of the tongue, and at retro molar area.^[23]

Clinically

- Homogeneous
- Erythroplakia with patch of leukoplakia
- Granular \speckled(6)

Pathophysiology



Differential diagnosis

- Inflammatory (immune)
- Infection
- Neoplasm.^[18]

Oral Submucous Fibrosis

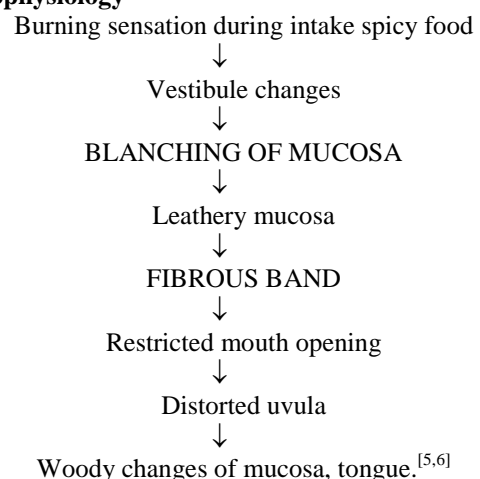
Oral sub mucous fibrosis is a potentially malignant disorder of oral cavity which causes oropharynx which is characterized by inflammation and increased fibrosis of the sub mucosal tissues resulting in marked rigidity and trismus.^[24] It leads to generalized epithelial atrophy as a high risk of precancerous condition.^[1] Ingredients of betel quid in different region are paan, gutka, pan masala, pan marag, mawa manipuri tobacco.^[25]

Mouth opening (interincisal)

Stage I - > 35 mm
 Stage II - 25 - 35 mm
 Stage III - 15 – 25 mm
 Stage IV - 5 – 15 mm
 Stage V - < 5.^[26]

Mainly caused region are soft palate and buccal mucosa and dysplastic conditions leads to squamous cell carcinoma.^[27] Clinically fibrosis and hyalinization of supraepithelial tissues are seen in this condition.^[28] Stages are divided according to changes of mucosal colour, texture, palpation of fibrous band and mouth opening.^[29]

Pathophysiology



Clinically

Fibrous bands formations are visible during palpation loss of tissue mobility, restricted mouth opening, and leathery mucosa.^[18] Fibrosis of uvula, tongue, hearing impairs and difficulty in swallowing is caused.^[30]

Tobacco Pouch Keratosis

Tobacco leaves chewing causes white mucosal lesion in the area of the contact.^[31] It occurs at buccal \ labial vestibule it may extend to the gingiva and buccal mucosa when tissue stretched wrinkling disappears.^[7]

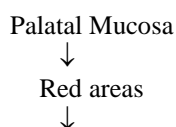
Reverse Smoking

It is well defined diffused greyish black pigmentation of the palate mucosa due to melanocyte, melanin increases against heat and toxic products.^[32] Drugs induced pigmented history of medication Premarin, Amodiaquine. Dark brown with less well defined borders associated with reverse smoking.^[33] In reverse smoking carcinoma occurs at posterior half of hard palate \ at anterior hard palate it based on glandular area of the palate.^[34]

Clinically

- Diffused whitening of palatal mucosa (keratosis)
- Everted nodules with centre red spots (excrescences)
- Elevated white plaques (patches)
- Reddening of palatal mucosa (red arms)
- Crater like areas covered by fibrin (ulcerated areas)
- Devoid of pigmentation.^[35]

Pathophysiology



- ✓ Ulceration
- ✓ Palatal keratosis → Palatal cancer (more common)
- ✓ Pigmentation
- ✓ Excrescence patches.^[35]

Lichen Planus

In the oral cavity lesions consisting of white, grey, reticular patches elevated white lines Wickham striae.^[36] It is asymptomatic, bilaterally \ symmetrically common at buccal mucosa, tongue, lips, gingiva, floor of the mouth and palate.

Clinically

Reticular, Erosive, Atropic plaque-like, Papular, Bulbous.^[37]

Management

- Counselling
- Surgical excision
- Laser technique
- Cryosurgery
- Vitamin A \ retinoid
- Iron supplement
- Hydrocortisone injection
- Cytopathology
- Vizilite
- Visualization adjuncts
- Vital tissue staining
- Stop smoking
- Visit dentist regularly for oral hygiene

- Cleaning teeth regularly to protect the oral cavity
- Ask of smoking at every opportunity
- Advise all smokers to stop
- Assess willingness to stop
- Assist the smoker to stop
- Arrangement follow up.^[38,39,7]

Drugs

- Nicotine replacement therapy(NRT): reduces smoking desire in smokers.
- Bupropion : Antidepressant
- Varenicline: recently used drugs.^[40]

ACKNOWLEDGEMENT: Nil.

CONFLICT OF INTEREST: None declared.

REFERENCE

1. L. Aravindh Etal Oral lesions associated with tobacco. Indian journal of drugs and diseases, 2012; 1(1).
2. WHO, Definition of precancerous lesion and condition, 1978.
3. Gupta etal an epidemiologic assessment of cancer risk in oral precancerous lesion, 1989 Jun 1; 63(11): 2247-52.
4. Awan K Etal Effects of tobacco use on oral health - an overview. Research. Gate, 2011; 18: 18-23.
5. Nishi Mishra, Shrivardhan K, Jayesh Rai, Nitin Awasthi. International Journal of Contemporary Medicine Surgery and Radiology. Tobacco related lesions of oral cavity- a review, 2017 feb 7; 2(1): 25-28.
6. Sabashvili M, Gigineishvili E, Jikia M, Chitaladze T (2018) Role of Tobacco in the Development of Oral Leukoplakia and Oral Cancer. Dentistry, 8: 495. doi:10.4172/2161-1122.1000495.
7. Eid HA and Musleh MM. Oral staining and Malodour Secondary to Tobacco Abuse in South-western Saudi: A Case Report. Austin J Dent, 2014; 1(2): 1006.
8. Neha Aggrawal, Sumit Bhateja Leukoplakia-Potentially Malignant Disorder of Oral Cavity -a Review Biomed Journal Scienfied technical research, 2018; 4(5): 4219-4220.
9. Mechili E. A., Girvalaki C., Saliq A., Filippidis F. T., Vardavas C. I. WHO FCTC Article 14 enforcement in Albania: An urgent issue to tackle. Tobacco Prevention & Cessation, 2019; 5(February): 6. doi:10.18332/tpc/103126.
10. Sofia etal smoking behaviour predicts tobacco control attitudes in high smoking prevalence hospital: A cross-sectional study in a Portuguese teaching hospital prior to the national smoking ban, 2011 Sep 23; 11: 720. doi: 10.1186/1471-2458-11-720.
11. Sayed M Mirbad etal Tobacco-Associated Lesions of the Oral Cavity: Part I. Non-malignant Lesions J Can Dent Assoc, 2000; 66: 252-6.

12. Gerd et al Systematic review of the relation b/w smokeless tobacco and non neoplastic oral diseases, 2008. 10.1186/1472-6831-8-13.
13. Michael fried man et al WebMD medical reference oral cancer sign and symptoms, Feb 17, 2015; 1-2.
14. Terry martin et al. Nicotine and the Developing Human: A Neglected Element in the Electronic Cigarette Debate. American journal of preventive medicine, 49(2), 286–293. doi:10.1016/j.amepre.2015.01.015
15. Carol E Cheng et al smokeless tobacco lesions. emedicine.medscape.com Jun 25, 2018.
16. Adriana spinal riberio et al review of non surgical treatment of oral leukoplakia International Journal of Dentistry, 2010. Article ID 186018, 10 pg.
17. Carrard VC, van der Waal I. A clinical diagnosis of oral leukoplakia; a guide for dentists. Med Oral Patol Oral Cir Bucal, 2018 Jan 1; 23 (1): e59- 64.
18. An international journal of otorhinolaryngology
19. Eli stag et al management of oral leukoplakia – analysis of the literature jimab, 2017; 231.1495.
20. Reichart PA, Philipsen HP. Oral erythroplakia—a review Oral Oncology, 2005; 41: 551 61.
21. Elaini sickert Hosni et al oral erythroplakia and speckled leukoplakia retrospective analysis Brazilian journal of otorhinolaryngology November, 2008; 75(2): 295-9.
22. Kajal Shilu et al, Kajal Shilu et al; International Journal of Advance Research and Development potentially malignant disorder and oral erythroplakia a review, 3(7): 18.
23. Burkett's Oral Medicine. Diagnosis and Treatment, 10th edn M A O Lewis, 2003. DOI: 10.1093/ortho/30.4.346.
24. Neelima Anil Malik Exodontias' text book of oral surgery 4 th edition.
25. Nektarious et al oral sub mucous fibrosis: background, pathophysiology, epidemiology dec 15, 2016: 1/11.
26. Deepak passi prateek Bhanet et al oral sub mucous fibrosis newer proposed classification with critical updates in pathogenesis and management stragies year, 2017; 8(2): 89-94.
27. Gernot jundat et al pathologicetal perspectives of non malignant lesions of the mouth DOI: 10.1016/B978-0-7020-6056-4.00088-5
28. S. Yadav, A. Verma, A Sachdeva, M Viridi. Etiopathogenesis and Management of Oral Sub mucous Fibrosis. The Internet Journal of Bioengineering, 2010; 5(1).
29. Shah N. Sharma Role of chewing and smoking halitosis in the etiology of oral sub mucous fibrosis case control study. in journal of oral pathology and medicine, 27(10): 475-9.
30. Uwe wollina et al oral sub mucous fibrosis clinically, 2015; 8: 193–204.
31. Pretty Mary Donald et al Tobacco pouch keratosis in a young individual a brief description journal of Indian society of periodontology yr, 2017; 21(3): 249-251.
32. Kimds etal temp regulates melanin synthesis in melanocytes, 2003 Oct; 26(10): 840-5.
33. Watson I B etal amodioquinine induced pigmentation.
34. Reddy CR Distribution of glands in the mucosa of the hard palate and its relation to carcinoma. J Oral Surg, 1976 Mar; 34(3): 232-6.
35. Goyal etal Precancerous lesions. IJMDS January, 2013; 2(1): 70.
36. Shafer textbook of oral pathology 7 Th edition.
37. Radwan-Oczko Topical application of drugs used in treatment of oral lichen planus lesions. Med, 2013 Nov-Dec; 22(6): 893-8.
38. Dereje N, Abazinab S, Girma A Prevalence and Predictors of Cigarette Smoking among Adolescents of Ethiopia: School Based Cross Sectional Survey. J Child Adolescent Behav, 2015; 3: 182. doi:10.4172/2375-4494.1000182.
39. Fiore MC, Bailey WC, Cohen SJ, et al. Rockville (MD): US Department of Health and Human Services, Public Health Service; Treating tobacco use and dependence. Clinical practice guideline, 2000.
40. Hurt RD, Sachs DP, Glover ED, Offord KP, Johnston JA, Dale LC, et al. A comparison of sustained-release bupropion and placebo for smoking cessation. N Engl J Med, 1997; 337: 1195–202.