

**CLASS 2 DISTOANGULAR THIRD MOLAR DISIMPACTION: A CASE REPORT**

**Juhi\*<sup>1</sup>, Abhishek Jain<sup>2</sup>, Sumera Pervaiz<sup>3</sup>, Himanshu Thukral<sup>4</sup>, Aditya Bansal<sup>5</sup>, Radhika Chadha<sup>6</sup> and Rajratna Sonone<sup>7</sup>**

<sup>1</sup>BDS, Patna, India.

<sup>2</sup>BDS FAGE MDS(Pedodontics 3rd Year).

<sup>3</sup>Intern, Sbb Dental College and Research Centre.

<sup>4</sup>MDS, Oral & Maxillofacial Surgeon, CEO Sarita Oral And Maxillofacial Center, Delhi.

<sup>5</sup>Consultant, Oral And Maxillofacial Surgeon, Madhya Pradesh.

<sup>6</sup>BDS, New Delhi.

<sup>7</sup>Consultant, Oral And Maxillofacial Surgeon, Akola Maharashtra.

**\*Corresponding Author: Juhi**

BDS, Patna, India.

Article Received on 31/03/2019

Article Revised on 21/04/2019

Article Accepted on 12/05/2019

**ABSTRACT**

Mandibular tooth impaction is a very common finding and is usually associated with so many local and systemic causes in which the pathway of tooth eruption is obstructed or misdirected. The local causes are either a local bony lesion or an abnormal position of the adjacent tooth. The case presented here is associated with a very rare cause of lingual impaction class 2 disimpaction.

**KEYWORDS:** Impaction, Third molar, Mandibular molar, Impacted thirdmolar.

**INTRODUCTION**

Several causes of impaction of the mandibular third molar have been described in the literature. Most common causes of the impaction of mandibular third molar are the abnormal positioning of the tooth bud, lack of space in the dental arch, supernumerary tooth ankylosis of the deciduous or permanent tooth, nonresorbing bone due to local or systemic causes, etc.<sup>[1,2]</sup> It is mainly due to bony obstruction in the pathway of eruption or the local adjacent tooth causes hindrance.<sup>[3]</sup>

All third molars need not be removed independent of disease findings and patients need not unnecessarily have to accept adverse consequences associated with the surgery risks and discomforts in the absence of pain, radiographic findings of pathology, and or marked clinical evidence of disease. However, when surgery is indicated several new concepts and techniques can prevent and or manage some of the common postoperative sequel of impacted mandibular third molar surgery.<sup>[5]</sup>

**CASE REPORT**

A 22- year-old female patient presented to the Cure 'n' Care Dental Clinic, Mayur Vihar, Delhi complaining of morbidity in the left third molar tooth. He was diagnosed

with chronic pericoronitis and informed that his mandibular third molar. Thereafter, the treatment options were explained to the patient, including the risks versus the benefits of surgically removing her impacted tooth. Following this discussion, the patient consented to proceed with surgical extraction of the impacted tooth. Tooth angulation can be a precise indicator for the prophylactic removal of partially erupted mandibular third molars<sup>[5]</sup>; the greater the degree of angulation of the third molar, the more difficult it is to remove. A current best practice for the surgical extraction of an impacted wisdom tooth is to first remove the crown portion in order to subsequently section and remove the root portion. The vertical incision was made at the mesial aspect of the buccal second molar. This was followed by adequate elevation of the mucoperiosteal flap. The alveolar bone overlying the crown was shaved to a groove with a round bur ensuring only minimal bony loss. The straight elevator is used to mobile and removal of tooth. The rationale for when to irrigate and mechanically debride the extraction socket in this case was twofold. Once the extraction socket was cleaned and sutures were placed solely on the alveolar bone beside the second molar. On post-operative day number five, suture was removed and the wound was found to be extremely clear. Now in post-operative year number three, the patient complains of none of the pre-operative morbidity with which she originally presented.

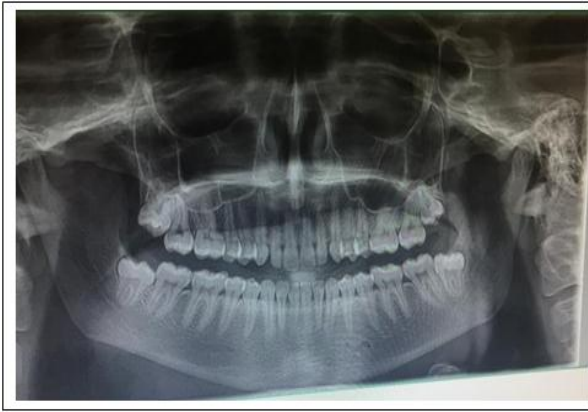

Fig 1: OPG.

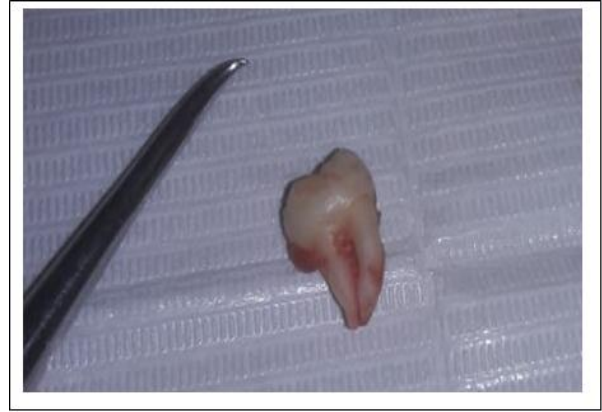

Fig 4: Extraction of 3<sup>rd</sup> Molar.

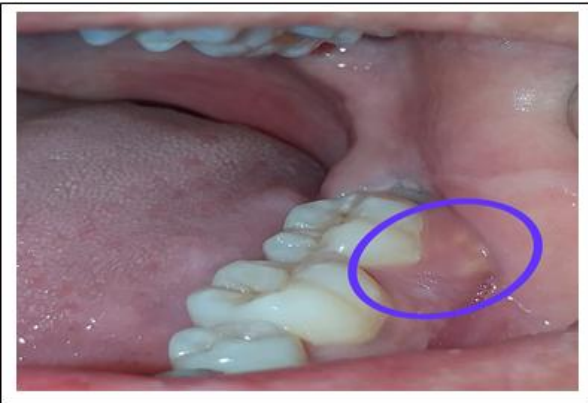

Fig 2: Pre-Operative Procedure.

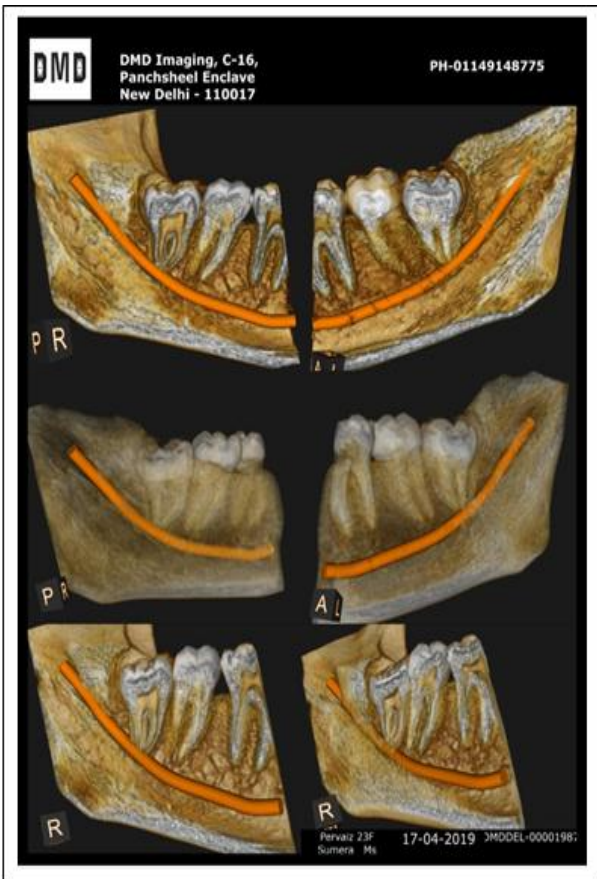


Fig 3: Cbct Profile Picture.

**DISCUSSION**

The true incidence and etiology of ectopic mandibular third molar remain unknown.<sup>[9]</sup> An aberrant eruption pattern has been suggested to occur when the tooth has been displaced by a lesion, usually an odontogenic cyst.<sup>[3,10,11]</sup> Dentigerous cyst is the most common benign lesion related to impacted mandibular third molar.<sup>[12]</sup> Over time, the pressure exerted by the intracystic fluid on the occlusal aspect of the third molar may cause its displacement, sometimes from its original location.<sup>[3,4,13]</sup>

In the present case, the mandibular third molar was not displaced by a cystic lesion but by an uncertain cause. The development of the tooth germ in an aberrant position or aberrant tooth germ eruption pattern may be the most likely etiology. Otherwise, primary and total dislocation of tooth base may be the cause.<sup>[8]</sup> In the process of mandibular skeletal growth, bone is typically added along the posterior ramus border and resorbed along the anterior border; mandibular condyle develops as a result of bone apposition in the posterior ramus.<sup>[14]</sup> In this case, the presence of dental caries implies that tooth dislocation occurred after its exposure to the oral cavity.

Keros and Susić<sup>[8]</sup> reported the ectopic mandibular third molar in the coronoid process and assumed that the bone forming the mandibular base in childhood may shift to the region beneath the coronoid process in adulthood, with the ectopic mandibular third molar embedded. Following the normal growth pattern, the third molar crown moved upward, eventually reaching the coronoid process of the mandible in non-inverted state.

Nonetheless, the etiology of ectopic impaction and migration of tooth is still unclear. Peck<sup>[15]</sup> reported that the intraosseous migration of impacted mandibular tooth is related to genetic determinants. According to Marks and Schroeder<sup>[16]</sup>, regional disturbance in the dental follicle might lead to local defective osteoclastic function, with an abnormal eruption pathway being formed. Sutton<sup>[17]</sup> believed that an abnormally strong eruption force or a change affecting the crypt of the tooth germ might lead to erroneous eruption.

Surgical extraction is mostly performed by an intra-oral approach. Extra-oral approach is done in extremely displaced impacted tooth cases. When teeth are located near the mandibular condyle, the preauricular approach can be used. The approach has the advantage of good exposure of the surgical site but may result in complications such as extraoral scar, damage to temporomandibular joint, and facial nerve injury.<sup>[11]</sup> The intraoral approach may avoid these problems, but access to and view of the severely displaced tooth may be limited; thus making the surgery difficult. In this case, the impacted tooth was located on the lingual side of the pterygomandibular space, and the surgery was performed using the intraoral approach. During the surgery, the inferior alveolar nerve should be protected. Moreover, excessive grinding of the coronoid process or mandibular condyle should not be done to prevent fracture.

Nowadays, most third molar extractions are performed when the patients are in their twenties, so the dislocation becomes rarer. Moreover, there may be patients with ectopic tooth without clinical symptoms, not knowing that they have a dislocated tooth. Therefore, annual panoramic radiograph taking from childhood is recommended for the early detection of ectopic third molar and its pathologic changes such as cyst formation and infection. Impacted teeth diagnosed upon routine radiographic examination--and which are not associated with any pathology--usually do not require treatment, but they should be removed to prevent cyst formation, infection, and weakening of the bone predisposing to fracture.<sup>[7]</sup> The surgical extraction of the ectopic third molar should be carefully planned and performed to minimize complications induced by surgery.<sup>[17]</sup>

## REFERENCES

1. Alling CC, 3rd, Catone GA. Management of impacted teeth. *J Oral Maxillofac Surg.*, 1993; 51(1,1): 3–6.
2. Kupferman SB, Schwartz HC. Malposed teeth in the pterygomandibular space: report of 2 cases. *J Oral Maxillofac Surg.*, 2008; 66: 167–169.
3. Bux P, Lisco V. Ectopic third molar associated with a dentigerous cyst in the subcondylar region: report of case. *J Oral Maxillofac Surg.*, 1994; 52: 630–632.
4. Tümer C, Eset AE, Atabek A. Ectopic impacted mandibular third molar in the subcondylar region associated with a dentigerous cyst: a case report. *Quintessence Int.*, 2002; 33: 231–233.
5. Medici A, Raho MT, Anghinoni M. Ectopic third molar in the condylar process: case report. *Acta Biomed Ateneo Parmense*, 2001; 72: 115–118.
6. Wassouf A, Eyrich G, Lebeda R, Grätz KW. Surgical removal of a dislocated lower third molar from the condyle region: case report. *Schweiz Monatsschr Zahnmed*, 2003; 113: 416–420.
7. Gadre KS, Waknis P. Intra-oral removal of ectopic third molar in the mandibular condyle. *Int J Oral Maxillofac Surg.*, 2010; 39: 294–296.
8. Keros J, Susić M. Heterotopia of the mandibular third molar: a case report. *Quintessence Int.*, 1997; 28: 753–754.
9. Bortoluzzi MC, Manfro R. Treatment for ectopic third molar in the subcondylar region planned with cone beam computed tomography: a case report. *J Oral Maxillofac Surg.*, 2010; 68: 870–872.
10. Salmerón JI, del Amo A, Plasencia J, Pujol R, Vila CN. Ectopic third molar in condylar region. *Int J Oral Maxillofac Surg.*, 2008; 37: 398–400.
11. Wang CC, Kok SH, Hou LT, Yang PJ, Lee JJ, Cheng SJ, et al. Ectopic mandibular third molar in the ramus region: report of a case and literature review. *Oral Surg Oral Med Oral Pathol Oral Radiol Endod.*, 2008; 105: 155–161.
12. Suarez-Cunqueiro MM, Schoen R, Schramm A, Gellrich NC, Schmelzeisen R. Endoscopic approach to removal of an ectopic mandibular third molar. *Br J Oral Maxillofac Surg.*, 2003; 41: 340–342.
13. Szerlip L. Displaced third molar with dentigerous cyst--an unusual case. *J Oral Surg.*, 1978; 36: 551–552.
14. Buschang PH, Gandini Júnior LG. Mandibular skeletal growth and modelling between 10 and 15 years of age. *Eur J Orthod.*, 2002; 24: 69–79.
15. Peck S. On the phenomenon of intraosseous migration of nonerupting teeth. *Am J Orthod Dentofacial Orthop.*, 1998; 113: 515–517.
16. Marks SC, Jr, Schroeder HE. Tooth eruption: theories and facts. *Anat Rec.*, 1996; 245: 374–393.
17. Sutton PR. Migration and eruption of non-erupted teeth: a suggested mechanism. *Aust Dent J.*, 1969; 14: 269–270.