

HISTOPATHOLOGICAL STUDY AND EFFECT OF ETHION IN DIFFERENT TISSUES OF *DANIO RERIO*

Vinayan K. V. and Tijare R. V.*

Department of Zoology, Govt. Institute of Science, R.T. Road, Civil Lines, Nagpur, India.



*Corresponding Author: Tijare R. V.

Department of Zoology, Govt. Institute of Science, R.T. Road, Civil Lines, Nagpur, India.

Article Received on 14/04/2025

Article Revised on 04/05/2025

Article Accepted on 26/05/2025

ABSTRACT

Ethion an organophosphate categorized as class II hazardous chemical as per WHO classification, which acts as an acetylcholinesterase inhibitor when reaches persistently to non-target organisms like aquatic life, raises environmental concerns, the accumulation in different tissues may cause serious damage leading to organ dysfunction. The current experiment was performed to investigate the changes in histology of selected tissues induced by ethion. The *Danio rerio* (Zebrafish) was subjected to three sublethal doses i.e. 0.340 mg/L, 0.476 mg/L and 0.612 mg/L at four-time intervals viz. 24 hours, 48 hours, 72 hours and 96 hours for any histological changes in gills, liver and muscle tissues. The histological changes were observed for different time periods and concentrations. It was evident from the current study that ethion has impacted adversely and caused histological changes in all 3 tissues under study. The histological examination has shown progressive adverse changes in gills, liver and muscles with increased doses and exposure time when compared to control. The histological changes in gills, liver and muscles can be used as bioindicator of eco-toxicity. So, it's imperative that there should be a judicious use of ethion and ecological concerns should be considered while use of ethion.

KEYWORDS: *Danio rerio*, Ethion, Histological, Organophosphate.

INTRODUCTION

India is an agrarian country and almost seventy percent of population depends on agriculture for their livelihood. Agriculture is the major employment source in India even after so much of industrialization. Currently India became the most populous country across the globe hence the demand for the food, increase in productivity is always a priority of the Government of the day. There is always search for innovations and techniques from the farmers in India to boost their yield. Pesticides are now an integral part of modern agriculture to control the pests and increase the yield. But in this due process, it's been observed that the over and non-judicious use of these chemicals is rampant. 50% of global use of pesticides is coming from Asia. With 0.31 kg per hectare use of pesticide India shares 1% of global use as per data of 2017.^[1] This indiscriminate use of harmful chemicals in agriculture had started impacting adversely for the non-target organisms.

Pesticides and chemicals used for agriculture purposes tends to remain in the soil and washed away with water to the nearby water bodies and adversely affect the aquatic ecosystem. The non-target organisms many times like fishes are part of food for humans, thus enter in the

human food chain also. These chemicals used mostly are highly toxic and only 1% of these chemicals reach the target and rest reaches to the non-targets causing serious repercussions.^[2]

Many of these chemicals have a short time of exposure for the non-target organisms because of rapid degradation, though the over-use of these had caused prolonged exposure resulting into ecological concerns especially for aquatic organisms.^[3]

The study of ecological toxicity in aquatic ecosystem caused by the pesticides is important to address the concerns of conservation and harmful effects on the aquatic organisms. As these chemicals present in the water bodies makes these aquatic organisms exposed by all means like respiration, ingestion and physical contact affecting all their body systems, it is pertinent to study various organs and tissues which will reflect the true toxic effect on these systems.^[4]

Environmental contamination of water by insecticides can be easily studied by subjecting the fishes to expose against these chemicals, as fishes are very sensitive to the changes of water quality and used as bioindicators for

such studies. These chemicals damage physiological and biochemical process of the living system and results into the impairment of physiological changes in fishes. Apart from the upfront toxic effects on the aquatic organisms, these chemicals show bio-accumulation in various tissues.^[5] The fishes are part of aquaculture and there are always a chance of these accumulated chemicals getting into the food chain which may result into serious health issues for other non-aquatic organisms too. For toxicity study on fishes Zebrafish (*Danio rerio*) is being commonly used globally because of easy availability, throughout year breeding, low cost and easy to maintain.^[6] Also references on histology of Zebrafish is available for a comparative study which makes the comparisons easy and accurate.

Ethion is an organophosphate insecticide which is categorized as moderately hazardous chemical as per WHO 2004 classification.^[7, 8] and commonly used for different crops like fruits, vegetables, tea, ornamental plants across India. Ethion, is lipophilic in nature and easily gets absorbed into the cells. Organophosphates inhibit the acetylcholinesterase enzyme required for the degradation of acetylcholine neurotransmitter from the synapses of nerves or junction of neuron and muscles, results into the accumulation of acetylcholine and causes the dysfunction of the muscles and leading to the death of the insects.^[9] There is no evidence of toxicity exerted by ethion on the organ system in adult *Danio rerio* so to determine the potential toxicity of ethion in multiple organs like gill, liver and muscle were assessed. Histopathologic observations were done to have an insight and understanding of pathological damage related to these tissues.^[10] The study of damages caused to the tissues are important tools in the ecotoxicological studies.^[22]

MATERIAL AND METHOD

The study protocol was submitted before ethics committee on animals IAEC Nagpur Veterinary College, Nagpur with proposal number NVC/IAEC/29/2022, receiving an approval and registration.

Procurement of Zebrafish and maintenance

The adult Zebrafish in required quantity were procured from the approved vendor. The adult fishes were of 6-7 months old with an average length of 4 ± 0.5 cm and weighs around 0.35 ± 0.2 gm were taken for experiment. Procured fishes were first dipped in 0.05% KMnO_4 solution as a precautionary measure to rule out any infection before transferring to the storage tank.^[12] The tank is made of glass with dimensions of 45 cm x 30 cm x 30 cm. This tank was also rinsed with 0.5% KMnO_4 solution before^[11] and then fishes were transferred to tank and kept for 30 days period as part of quarantine and allowed to acclimatize to the new conditions.^[11] The tank was filled with dechlorinated tap water and maintained the desired volume by restoring with fresh water. The fishes were fed with commercially available dry pellets containing protein, fibre and fat extracted

from corn, soyabean. The dry pellets were first crushed to feed the zebrafish. Less than 2% mortality was seen during first 48 hours of arrival which was within the accepted limits. The mortalities could be due to the stress and new conditions. Water level was kept at a pre-decided volume during the acclimatization period and tank was routinely cleaned to remove the faecal matter and uneaten food by using the syphon pipe. Forty percent of water changed on daily basis along with the cleaning of the tank.

The photoperiod of fishes was 12 hours light and 12 hours dark were maintained strictly by using a timer switch. The water parameters were maintained as per the CCAC guidelines 2020 on Zebrafish.^[13] The pH of water was kept at 7 ± 0.4 measured by pH meter which was calibrated as per manufacturer's instructions.^[14] Temperature was maintained at $26 \pm 2^\circ\text{C}$.^[14] The dissolved oxygen was maintained at 6 ± 0.1 ppm.^[15] Also, other water parameters were well maintained during the entire study like TDS/EC/Salinity/SG. The TDS was 175 ± 2 ppm; salinity 0.01 ppm and specific gravity was 1.001. The conductivity as per guidelines was maintained at 360-370 $\mu\text{S}/\text{cm}$.^[16]

Commercially available ethion with the brand name Tafethion manufactured and marketed by Rallis India Limited Hyderabad India was procured from the local market of Nagpur. Tafethion is available in 50% EC 54.5% w/w. Micropipettes were used to withdraw ethion and to make the stock solution.

The study of effect of ethion in different tissues of *Danio rerio* includes first the determination of LC_{50} for ethion in *Danio rerio*. Percentage mortality was calculated for each dose for 24 hours, 48 hours, 72 hours and 96 hours based on the number of mortalities happened for each exposure time. LC_{50} value was determined using Log dose/Probit regression line method at 95% confidence interval.^[20] Based on the LC_{50} value three sublethal doses is calculated and its effect on gills, liver and muscle tissues of *Danio rerio* at four-time intervals viz... 24 hours, 48 hours, 72 hours and 96 hours were evaluated.

Histopathology

Histopathological analysis was performed for gills, liver and muscles of *Danio rerio*. The fishes were euthanised by immersing in ice water bath at temperature 4°C ^[17] for 40 minutes and followed by dissection. Tissue samples from the gills, liver and muscle were fixed in 10% neutral buffer formalin and followed by fixation,^[18] tissues were dehydrated with a graded series of alcohols and cleared in xylene, embedded in paraffin wax to prepare the tissue blocks. After section cutting using a rotary microtome of 5 μm thickness, sections were stained with haematoxylin and eosin.^[19] The analysis of slides was performed under an optical microscope Karl Zeiss Primo star microscope and photographed with Tucsen camera H series.

OBSERVATIONS

The potential changes caused post exposure of ethion in gills, liver and muscles of *Danio rerio* were observed and elucidated at histological study.^[23] During this study no changes were observed in gills, liver and muscle tissues of *Danio rerio* in control arm for different time periods.

Histopathological changes in gills of *Danio rerio*

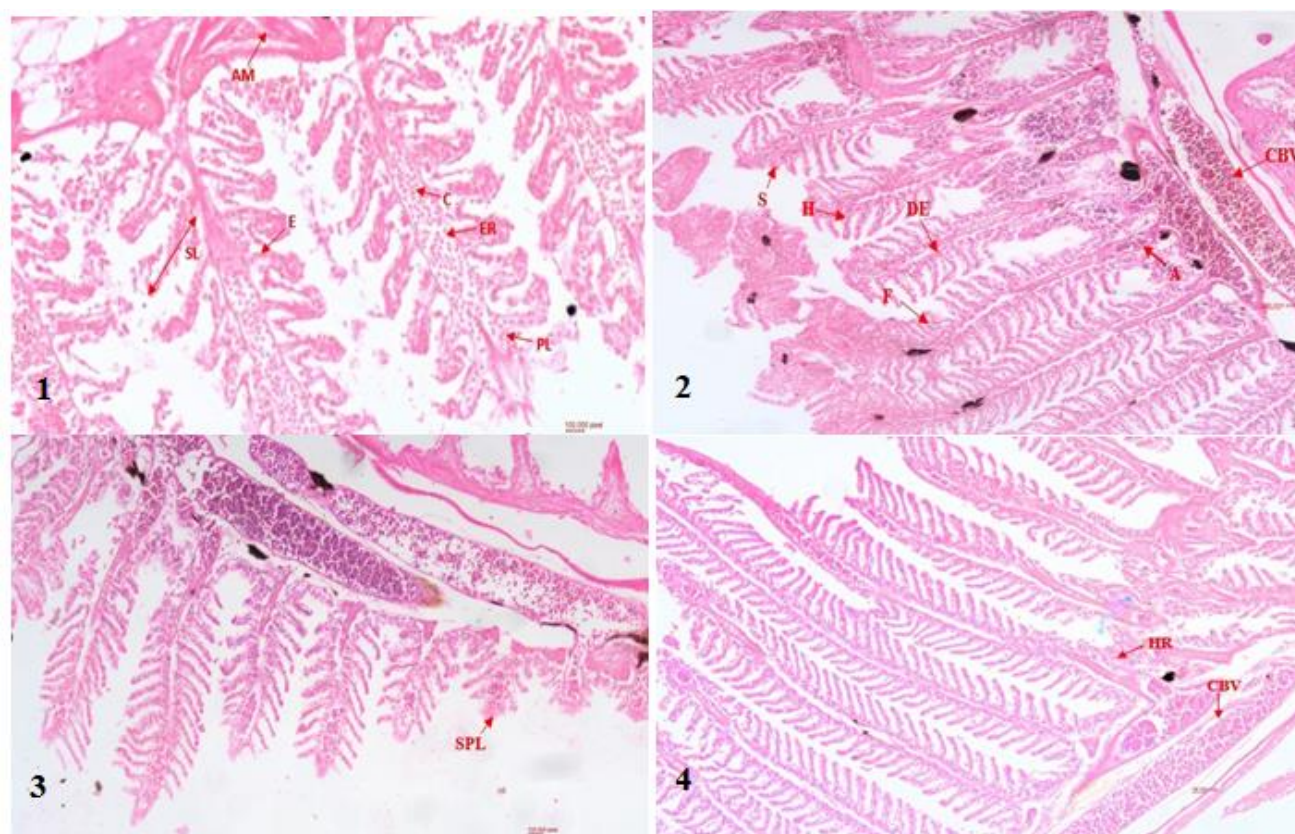
Gills are the first organ that gets exposed to the environment which is highly sensitive to the toxic compounds and shows tissue changes. These changes always affect the respiratory system and cause detrimental damage to fishes. The gills of *Danio rerio* has shown alterations on exposure to ethion at sublethal doses at different time intervals.

At a dose of 0.340 mg for 24-hours and 48-hours duration displacement of epithelium and shortening of primary lamellae in gills, sloughing of secondary lamellae, hypertrophy in secondary lamellae, fusion of secondary lamellae takes place in gills. During 72 hours mild haemorrhage and mild necrosis, hypertrophy in secondary lamellae, fusion of secondary lamellae in gills was observed while for 96 hours duration severe

haemorrhage, secondary lamellae sloughing, congestion in blood vessels, mucosal secretion in gills was observed.

During 0.476 mg dose displacement of epithelium and fusion of secondary lamellae in 24 hours was noticed. At 48 hours and 72 hours shortening of primary lamellae and haemorrhages in mucosal space along with sloughing of both primary and secondary lamellae and mild haemorrhage, hypertrophy in secondary lamellae and fusion of lamellae was observed. In 96 hours, duration severe haemorrhages in mucosal space and shortening of primary lamellae with sloughing of both primary and secondary lamellae of gills was observed.

For 24 and 48 hours, at dose of 0.612 mg, congestion & haemorrhages in the mucosal space, in between gill lamellae and sloughing of secondary lamellae, mucosal secretion of gills observed respectively. Sloughing of primary & secondary lamellae along with shortening of primary lamellae, with slight necrotic changes in gills was noted during 72 hours while sloughing and fusion of primary lamellae along with massive haemorrhage between the lamellae and in mucosal space of gills observed in 96 hours duration.



1) Normal morphology of primary & secondary lamellae *Danio rerio*, AM- adductor muscle, SL- secondary lamellae, PL- primary lamellae, ER- erythrocyte, C- chondrocyte, E- epithelial cells. 2) H- hypertrophy of secondary lamellae, DE- displacement of epithelium, A- aneurysm CBV- congestion in blood vessel, F- fusion of secondary lamellae. 3) SPL- shortening of primary lamellae, S- sloughing of primary and secondary lamellae. 4) HR- haemorrhage, CBV- congestion in blood vessel

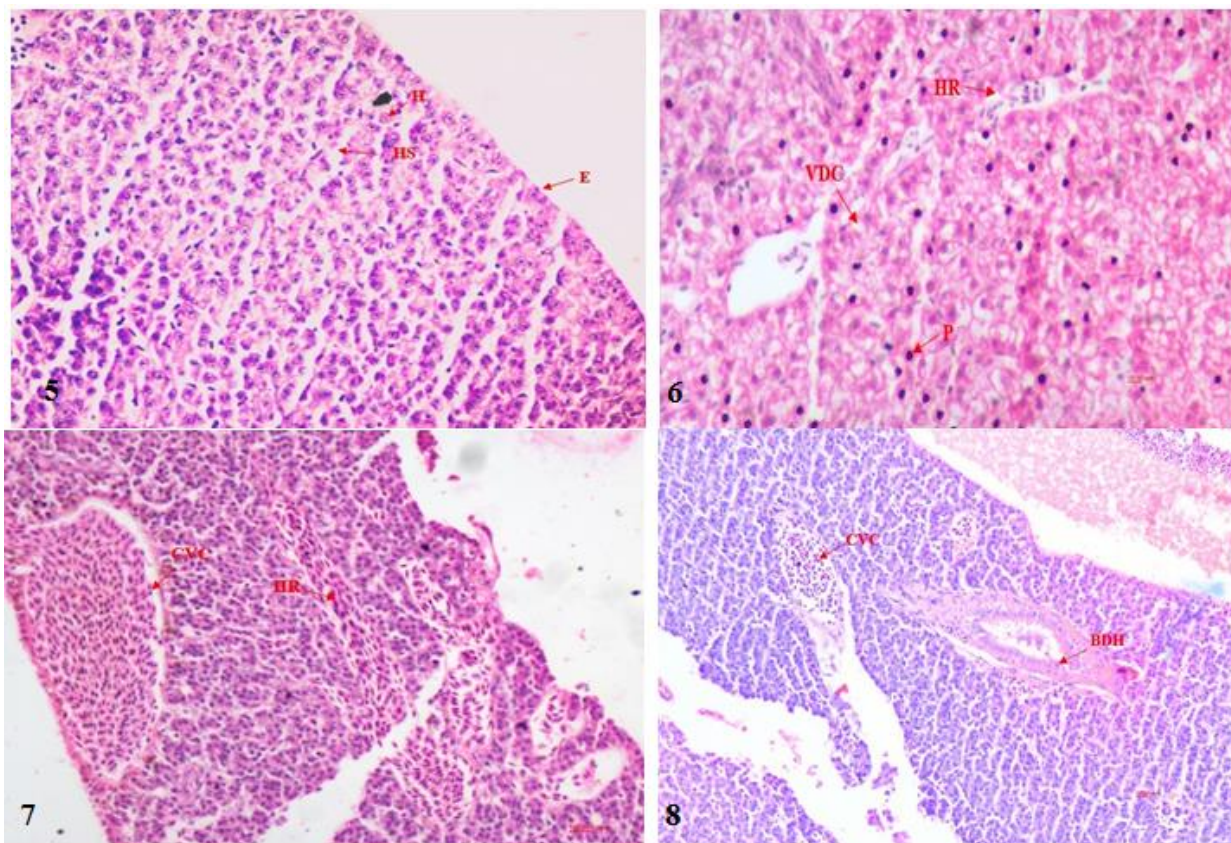
Histopathological changes in *Danio rerio* liver

Liver in *Danio rerio* has a very thin serosa and composed of squamous epithelium having a spindle shaped nucleus.^[24] Hepatocytes are primary cells in liver with spherical nucleus and distributed throughout in spotted manner. Bile duct openings and blood vessels openings can be seen in between hepatocytes. Hepatic sinusoid can also be seen in between especially in livers of female zebrafish.^[24]

At the dose of 0.340 mg for 24 hours duration Congestion in central vein in liver was seen. At 48 hours further progressive changes were seen like haemorrhages and degenerative changes in hepatocytes. More severe changes were observed in liver tissues as the tissues exposed for longer period of time. At 72 hours severe congestion in central vein and haemorrhages between hepatocytes and at 96 hours, haemorrhages between the hepatocytes, severe vacuolar degenerative changes in hepatocytes leading to fatty liver and pyknosis of nuclei of hepatocytes was observed.

For 0.476 mg of sublethal dose during 24 hours, congestion on central vein along with pyknosis of nuclei of hepatocytes was noted. At 48 and 72 hours pyknosis along with degenerative changes in hepatocytes & haemorrhage between hepatocytes and congestion in central vein observed respectively while in 96 hours severe congestion in central vein, pyknosis & degenerative changes in hepatocytes were observed.

At dose of 0.612 mg congestion in central vein and mild degenerative changes in hepatocytes was observed during 24 hours treatment. Pyknosis and degenerative changes in hepatocytes of liver along with bile duct hyperplasia Pyknosis and severe vacuolar degenerative changes in hepatocytes leading to fatty changes was observed in 48 and 72 hours and severe congestion in central vein and bile duct hyperplasia was observed in 96 hours.



5) Normal morphology *Danio rerio* liver 6) HR- haemorrhage, VDC- vacuolar degenerative changes, P-pyknosis. 7) CVC- central vein congestion, HR- haemorrhage. 8) BDH- bile duct hyperplasia, CVC- central vein congestion

Histopathological changes in *Danio rerio* muscle

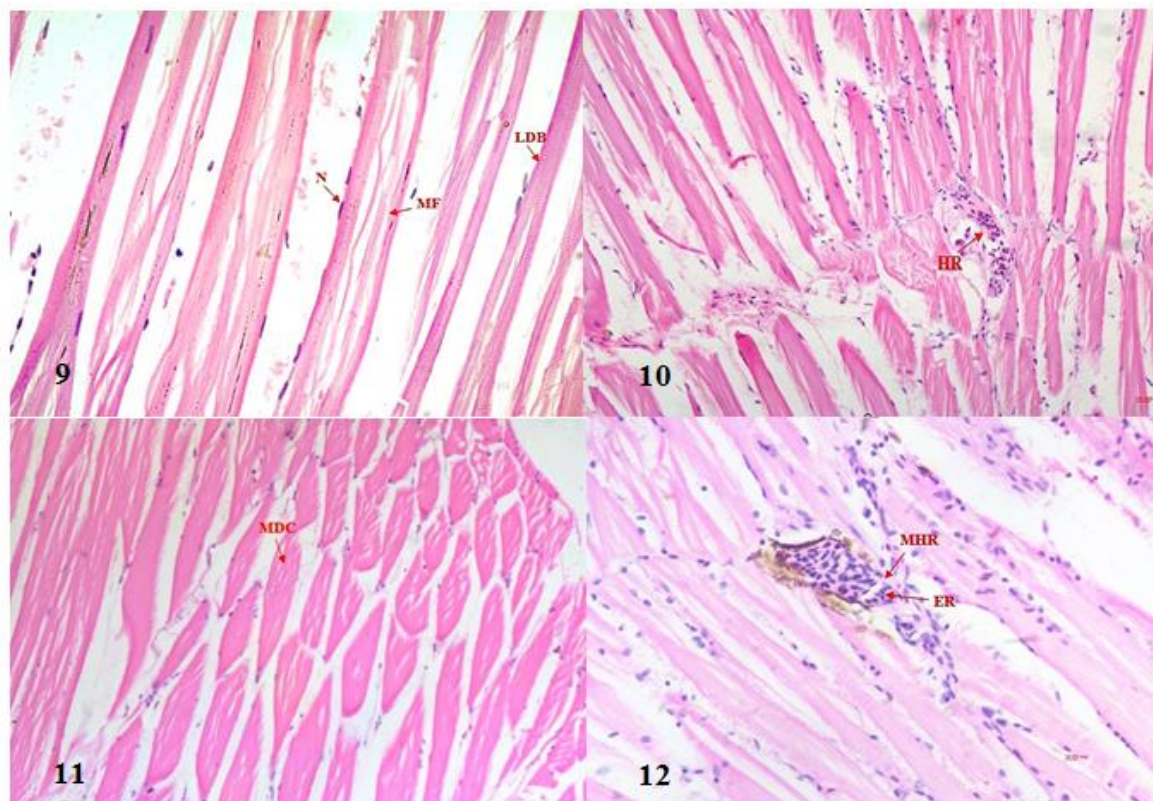
Muscle fibres are long, thin, fibrous and straited. The myocytes are long cylindrical and multinucleated cells with oval nuclei, normally presented at the edge of myofibers.^[25] The effects of sublethal doses are observed under the microscope for any changes post exposure to ethion. Majorly haemorrhage between myofibrils are seen and some degenerative changes were seen.

At dose of 0.340 mg normal morphology of muscle fibers was observed during 24 and 48 hours. Haemorrhages between muscle fibers with degenerative changes in muscle fibers and massive haemorrhages between muscle was observed in 72 and 96 hours respectively.

During sublethal dose of 0.476 mg mild degenerative changes in muscle fibers was occurred in 24 and 48 hours while moderate degenerative changes and degenerative changes in muscle fibers was observed during 72 and 96 hours.

For 0.612 mg sublethal dose of ethion mild degenerative changes in muscle fibre was observed during 24-hours

and 48-hours treatment. Haemorrhages between the muscle fibre along with degenerative changes in 72 hours and massive haemorrhages, loss of striated muscle, muscle degradation and necrosis were noted during 96 hours.



9) disintegration of muscle fibre in *Danio rerio* muscle N- nucleus of muscle fibre, MF- muscle fibre, LDB- light & dark band. 10) HR- haemorrhage 11) MDC- mild degenerative changes 12) MHR- massive haemorrhage, ER- erythrocytes

DISCUSSION

As per WHO classification 2004, ethion is category II moderately hazardous chemical, but it is evident from the study that ethion exerts serious damages to the tissue which ultimately affecting the body's organ system. The LC_{50} value of Ethion for *Danio rerio* in a static system is 0.912 mg/L.

Ethion is an organophosphate which acts as an acetylcholinesterase enzyme inhibitor. Acetylcholinesterase enzyme hydrolyses the acetylcholine neurotransmitter which is required for a systemic excitation and then relaxation of nerve impulse leading to normal functioning of neurons and muscles.^[9] As ethion inhibits this enzyme, the normal function gets impaired leading to the dysfunction of the muscles and nerve which cause death of the organism. This study clearly establishes the detrimental impact of ethion on various tissues.

Gills play an important role in the oxygenation of the blood, osmoregulation and detoxification in fishes. Gills consist of primary and secondary lamellae which comes in direct contact with the flowing water currents due to which it is exposed to any compound present in the water. Secondary lamellae externally have a layer of epithelial cells separated by pillar cells.^[24] These epithelium layer shows alteration on exposure to any toxic compound, gets displaced and lifting of the epithelium lining of the lamellae occurs supported by many studies.^[26] This is an adaptive way to adjust to the changing environment surroundings where there is an uptake of water in between the spaces of epithelium but this change would lead to suffocation for the fish.^[27] There is hypertrophy of epithelial cells due to which secondary lamellae get fused together resulting in blockage of exchange of gases through water. This was observed with increasing exposure time. The sloughing of secondary lamellae was seen as exposure time increase and necrosis was also observed. Haemorrhages also observed in secondary lamellae and between

mucosal space. The shortening of primary lamellae is evident. These alterations in the gill tissue results in the collapse of normal functioning ultimately leading to the death of the *Danio rerio*. This study not included the recovery of the fishes beyond 96 hours, how the *Danio rerio* recovers the exposure period of ethion is unexplored.

In *Danio rerio* liver is a thin and an elongated organ divided into three parts. Liver has a thin layer of serosa and has the squamous epithelium. There is a double layer of hepatocytes arranged in plates scattered around the central vein.^[24] Liver in *Danio rerio* showed alterations in morphology post exposure to ethion which was dose and time dependant. There are condensation of nucleus and degenerative changes shown in early stages of exposure and in all concentration indicating that liver of *Danio rerio* is sensitive to ethion. Apart from pyknosis, necrotic effect and congestion of central vein was also observed. Necrotic effect can cause the functional loss of liver which could be detrimental for the fish. The congestion of blood vessels and central vein results into the decrease in blood flow can cause atrophy in the neighbouring area leads to necrotic changes because of reduced metabolic supply to the tissues.^[28] Hyperplasia was observed in bile duct as an effect to the exposure to toxic compound. Severe vacuolar degenerative changes in hepatocytes leading to fatty changes were observed with the increasing concentration and time of exposure. Vacuolization and atrophy are often preceding the pyknosis and leads to degenerative changes in liver.^[29] Liver as an organ is a sensitive bioindicator for the evaluation of toxic effects of toxic compounds in the aquatic ecosystem.^[30]

Exposure of sublethal concentration of ethion has produced histological abnormalities in the muscle of *Danio rerio*. Though at lower concentrations and early exposure, there were no histological changes observed but as the exposure time and concentrations increased, the changes were evident. The haemorrhages between the myofibrils seen with erythrocytes infiltration and degenerative changes were also observed. The muscle fibre degradation and loss of striated muscle clearly indicating the impact of ethion on the muscles. These changes affect the contractile function of the muscles and results in the movement of the fishes.^[31] The loss of striations in muscle, disintegrated muscle, degradation and necrosis is seen

CONCLUSION

From the study, the LC50 value for Ethion in *Danio rerio* is 0.912 mg/L and ethion has caused alterations in the histology of gills, liver and muscles. It is clearly evident that ethion is harmful and detrimental for *Danio rerio* at sublethal concentrations. Ethion adversely impacts *Danio rerio* at each of these tissues which are incalculable damages important for the normal functioning of the fish life. These tissue alterations in gills, liver and muscles are time and concentration

dependant and was evaluated for 96 hours. The recovery phase beyond this time period was beyond the scope of this study which needs in detail investigations. Prolong exposure of ethion is harmful to the aquatic ecosystem and higher chances of tissue accumulation is the potential risk for other organisms also which needs to be investigated. From the study it is clearly evident that ethion is a threat to the non-target organisms and judicious use of these compounds are warranted.

ACKNOWLEDGEMENT

The authors are very much thankful to Director, Institute of Science, R.T. Road, Civil Lines, Nagpur for providing necessary research resources to carry out the study and Associate Dean, Nagpur Veterinary College, Nagpur for giving permission to conducting the experiments on fishes.

CONFLICT OF INTEREST

The authors declared no potential conflicts of interest with respect to the research, authorship.

REFERENCE

1. Pragati Nayak & Prof. Dr. Hitesh Solanki, Pesticides and Indian Agriculture – A Review. International Journal of Research – Granthaayah., 2021; 9(5): 250.
2. Rand, G.M. and Petrocelli, S.M. Fundamentals of Aquatic Toxicology Methods and Applications. New York; McGraw-Hill, 1984; 666.
3. Ramesh Halappa and Muniswamy David. Behavioural Responses of the Freshwater Fish, *Cyprinus carpio* (Linnaeus) following Sublethal Exposure to Chlorpyrifos. Turk. J. Fish. Aqua, Sci., 2009; 9: 233-238.
4. Graham R. Scotta, Katherine A. Sloman. The effects of environmental pollutants on complex fish behaviour: integrating behavioural and physiological indicators of toxicity. Aquatic Toxicology, 1993; 68(2004): 369–392.
5. Farid Soliman Sabra and El-Sayed El-Deeb Mehana. Asian Journal of Agriculture and Food Sciences, 2015; 03(1): 2321 – 1571.
6. Guofeng Jia, Xiecheng Liu. The acute toxicity of Oxydemeton-methyl in zebrafish. BioRxiv, 2017.
7. The WHO recommended classification of pesticides by hazard and guidelines to classification 2004 prepared by Inter-organization program for the sound management chemicals, 2004.
8. National Pesticide Information Centre (NPIC) updated pesticide fact sheets <https://extoxnet.orst.edu/pips/ethion.htm>
9. T. Roy Fukuto. Mechanism of Action of Organophosphorus and Carbamate Insecticides. Environmental Health Perspectives, 1990; 87: 245-254.
10. Bangeppagari Manjunatha, Eunseok Seo, Deekshitha Bangyappagari, Sang Joon Lee. Histopathological and ultrastructural alterations reveal the toxicity of particulate matter (PM 2.5) in

- adult zebrafish. *Journal of Hazardous Materials Advances*, 2022; 100135.
11. Md. Ariful Islam, S. M. Nurul Amin, Christopher L. Brown, Abdul Shukor Juraimi, Md. Kamal Uddin, Aziz Arshad. Determination of Median Lethal Concentration (LC50) for Endosulfan, Heptachlor and Dieldrin Pesticides to African Catfish *Clarias gariepinus* and their Impact on its behavioural patterns and histopathological Responses. *Toxics*, 2021; 9: 340.
 12. Rakesh Soni, Sushant Kumar Verma, Acute toxicity and behavioural responses in *Clarias batrachus* (Linnaeus) exposed to herbicide pretilachlor. *Heliyon*, 2018; 4.
 13. Guidelines of CPCSEA for Experimentation on Fishes, 2021.
 14. Lawrence. The husbandry of zebrafish (*Danio rerio*): A review. *Aquaculture*, 2007; 269: 1-20.
 15. Matthews et al. *Aquatic Toxicology Methods and Applications*. New York; McGraw-Hill: 2002; 666.
 16. Avdesh et al. Regular Care and Maintenance of a Zebrafish (*Danio rerio*) Laboratory: An Introduction. *Journal of Visualized Experiments*, 2012; 69.
 17. CCAC guidelines: Zebrafish and other small, warm-water laboratory fish, prepared by Canadian Council on Animal Care, 2020.
 18. Anna Pecio and Rafal P. Piprek. *The Histology of Fishes*; CRC Press Taylor & Francis Group 2019; 1-5.
 19. Dr. S. Kim Suvarna, Dr. Christopher Layton and Mr. John D. Bancroft: *Theory and Practice of Histological Techniques*: 7th edition., Churchill Livingstone Elsevier, 2012; 83-184.
 20. Finney, D.J. *Probit Analysis*. 3rd Edition, Cambridge University Press, London, 1971.
 21. Akanksha Singh and Dr Kannez Zahra. LC50 assessment of cypermethrin in *Heteropneustes fossilis*: Probit analysis. *International Journal of Fisheries and Aquatic Studies*, 2017; 5(5): 126-130.
 22. Santos, D.C.M., Cupertino, M.C., Matta, S.L.P., Oliveira, J.A., Santos, J.A.D. Histological alterations in liver and testis of *Astyanax aff. bimaculatus* caused by acute exposition to zinc. *Rev. Ceres, Viçosa*, 2015; 62(2): 133-141.
 23. Bangeppagari Manjunatha, Eunseok Seo, Deekshitha Bangyappagari, Sang Joon Lee. Histopathological and ultrastructural alterations reveal the toxicity of particulate matter (PM 2.5) in adult zebrafish. *Journal of Hazardous Materials Advances*, 2022; 100135.
 24. Jinxing_Lin, Qiusheng_Chen, Jianhua_Hu. *Color Atlas of Zebrafish Histology and Cytology*, Singapore; Springer Nature, 2022; 83-118.
 25. Aswin L. Menke, Jan M. Spitsbergen, Andre P.M. Wolterbeek, Ruud A. Woutersen. *Normal Anatomy and Histology of the Adult Zebrafish*. *Toxicologic Pathology*, 2011; 39: 759-775.
 26. Carvalho, J.C.T., Keita, H., Santana, G.R., de Souza, G.C., dos Santos, I.V.F., Amado, J.R.R., Kourouma, A., Prada, A.L., Carvalho, H.O., Silva, M.L. Effects of *Bothrops alternatus* venom in zebrafish: a histopathological study. *Inflammopharmacology*, 2018; 17: 273-284.
 27. Campagna, A.F., Fracacio, R., Rodrigues, B.K., Eler, M.N., Fenerich-Verani, N, Espindola, E.L.G. Effects of the copper in the survival, growth and gill morphology of *Danio rerio* (Cypriniformes, Cyprinidae). *Acta Limnologica Brasiliensia*, 2018; 20: 253-259.
 28. Roberts, R. J. *Fish pathology*. 4th edition., London; Wiley-Blackwell, 2012.
 29. Raphaelle Sousa Borges, Arlindo César Matias Pereira1, Gisele Custodio de Souza and José Carlos Tavares Carvalho. *Histopathology of Zebrafish (Danio rerio) in Nonclinical Toxicological Studies of New Drugs*. *Zebrafish Research*, 2019; 1-14. DOI: <http://dx.doi.org/10.5772/intechopen.88639>
 30. Antônio Figueiredo-Fernandes, Jorge V. Ferreira-Cardoso, Sofia Garcia-Santos, Sandra M. Monteiro, João Carrola, Pedro Matos. Histopathological changes in liver and gill epithelium of Nile tilapia, *Oreochromis niloticus* exposed to waterborne copper. *Pesq. Vet. Bras.*, 2007; 27(3): 103-109.
 31. Lakshmaiah, G. Toxic effect of Phorate on the histopathology of muscle in the fresh water fish *Cyprinus carpio* exposed to lethal concentrations. *International Journal of Current Research*, 2016; 8(6): 32362-32365.